

New International Guidelines and Consensus on the Use of Lung Ultrasound

Libertario Demi, PhD , **Frank Wolfram, PhD**, **Catherine Klersy, PhD**, **Annalisa De Silvestri, PhD**, **Virginia Valeria Ferretti, PhD**, **Marie Muller, PhD**, **Douglas Miller, PhD**, **Francesco Feletti, PhD**, **Marcin Wełnicki, PhD** , **Natalia Buda, MD** , **Agnieszka Skoczylas, MD**, **Andrzej Pomiecko, PhD**, **Domagoj Damjanovic, PhD**, **Robert Olszewski, MD**, **Andrew W. Kirkpatrick, MD** , **Raoul Breikreutz, PhD**, **Gebhart Mathis, MD**, **Gino Soldati, MD**, **Andrea Smargiassi, PhD** , **Riccardo Inchingolo, PhD** , **Tiziano Perrone, PhD** 

Received March 7, 2022, from the Department of Information Engineering and Computer Science, University of Trento, Trento, Italy (L.D.); Department of Thoracic and Vascular Surgery, SRH Wald-Klinikum Gera, Gera, Germany (F.W.); Unit of Clinical Epidemiology and Biostatistics, Fondazione IRCCS Policlinico S. Matteo, Pavia, Italy (C.K., A.D.S., V.V.F.); Department of Mechanical and Aerospace Engineering, North Carolina State University, Raleigh, North Carolina, USA (M.M.); Department of Radiology, Michigan Medicine, Ann Arbor, Michigan, USA (D.M.); Department of Diagnostic Imaging, Unit of Radiology of the Hospital of Ravenna, Ausl Romagna, Ravenna, Italy (F.F.); Department of Translational Medicine and for Romagna, Università Degli Studi di Ferrara, Ferrara, Italy (F.F.); 3rd Department of Internal Medicine and Cardiology, Medical University of Warsaw, Warsaw, Poland (M.W.); Department of Internal Medicine, Connective Tissue Disease and Geriatrics, Medical University of Gdansk, Gdansk, Poland (N.B.); Geriatrics Department, National Institute of Geriatrics, Rheumatology and Rehabilitation, Warsaw, Poland (A.S.); Clinic of Pediatrics, Hematology and Oncology, University Clinical Center, Gdansk, Poland (A.P.); Heart Center Freiburg University, Department of Cardiovascular Surgery, Faculty of Medicine, University of Freiburg, Freiburg, Germany (D.D.); Department of Gerontology, Public Health and Didactics, National Institute of Geriatrics, Rheumatology and Rehabilitation, Warsaw, Poland (R.O.); Departments of Critical Care Medicine and Surgery, University of Calgary and the TeleMentored Ultrasound Supported Medical Interventions Research Group, Calgary, Canada (A.W.K.); FOM Hochschule für Ökonomie & Management gGmbH, Department of Health and Social, Essen, Germany (R.B.); Emergency Ultrasound, Austrian Society for Ultrasound in Medicine and Biology, Vienna, Austria (G.M.); Diagnostic and Interventional Ultrasound Unit, Valledel Serchio General Hospital, Lucca, Italy (G.S.); Pulmonary Medicine Unit, Department of Medical and Surgical Sciences, Fondazione Policlinico Universitario A. Gemelli IRCCS, Rome, Italy (A.S., R.I.); Department of Internal Medicine, IRCCS San Matteo Hospital Foundation, University of Pavia, Pavia, Italy (A.S., R.I.); and Emergency Department, Humanitas Gavazzoni, Bergamo, Italy (T.P.). Manuscript accepted for publication July 31, 2022.

Riccardo Inchingolo and Tiziano Perrone equally contributed and are co-last authors.

The authors declare no conflict of interest.

Address correspondence to Libertario Demi, Head of Ultrasound Laboratory Trento, Department of Information Engineering and Computer Science, University of Trento, Trento (TN), Italy; Via Sommarive, 9 - 38123 Povo (TN), Italy.

E-mail: libertario.demi@unitn.it

doi:10.1002/jum.16088

This is an open access article under the terms of the [Creative Commons Attribution-NonCommercial-NoDerivs License](#), which permits use and distribution in any medium, provided the original work is properly cited, the use is non-commercial and no modifications or adaptations are made.

Following the innovations and new discoveries of the last 10 years in the field of lung ultrasound (LUS), a multidisciplinary panel of international LUS experts from six countries and from different fields (clinical and technical) reviewed and updated the original international consensus for point-of-care LUS, dated 2012. As a result, a total of 20 statements have been produced. Each statement is complemented by guidelines and future developments proposals. The statements are furthermore classified based on their nature as technical (5), clinical (11), educational (3), and safety (1) statements.

Key Words—A-lines; artificial intelligence; B-lines; COVID-19; lung ultrasound; lung ultrasound protocols; lung ultrasound standardization; LUS safety assurance; point of care ultrasound; post-COVID-19; quantitative ultrasound; SARS-CoV-2; sonographic interstitial syndrome; vertical artifacts

Introduction

Ten years have passed since the first international consensus on the use of lung ultrasound (LUS) was published in 2012. LUS, compared with other imaging modalities, offers several important advantages, that is, real-time imaging, use of nonionizing radiation, reduced equipment cost, portability, and bedside availability. Consequently, LUS adoption has been growing significantly since 2012.

In this period of time, many studies introduced significant novelty to the field of LUS thus requiring an update of the original consensus. Moreover, the spread of COVID-19 has accelerated several processes that were already undergoing in the international community, as the need for a standardized and evidence-based approach was urgently felt.

As an additional element of novelty, in this new consensus, we aim at expanding the competencies of the authors beyond those of the original consensus, which were limited to the clinical domain. To this end, expertise from engineers and physicists has been included, thus complementing the clinical viewpoints with

essential elements concerning image formation and processing, ultrasound (US) propagation physics, as well as safety aspects related to the interaction of US fields with matter. This enrichment has the effect of increasing the strength of the document, by ensuring a wider validity across multiple scientific domains and by fostering a much-needed collaboration between clinicians, engineers, and physicists, which is fundamental for the development of reproducible and reliable US solutions dedicated to lung tissue. This approach is reflected in the structure of the formulated statements. Indeed, the 20 statements which have been formulated in this consensus are classified as technical (5), safety (1), clinical (11), and educational (3) statements. Each statement is also completed by guidelines and future developments proposals.

The article is organized as follows. First, the method implemented to produce and evaluate the statements, guidelines, and future developments is described in the Section 2. Next, each statement is introduced together with the corresponding guidelines and envisioned future developments, followed by a detailed description of the scientific evidence and motivations that support the statement. Not all statements are associated with unique guidelines and/or future developments proposals. In case the same, or part of, guidelines and/or future developments proposals are shared among statements, they are explicitly repeated in the manuscript to improve readability. All statements are also provided through Table 1, which also indicates their classification.

The article ends with the discussion and conclusions sections.

Materials and Methods

A two-step modified Delphi method was implemented.

Panel Selection

A Core Group of LUS experts (more than 10 years of experience in LUS) has spontaneously formed, including multiple professional figures that would benefit from clinical practice guidelines (Pneumologists, Intensivists, Radiologist, Cardiologists, Internal Medicine, and Engineers/Physicists). These experts were identified from Europe, Canada, and the United States; and

selected based on their clinical and research expertise in LUS. All these experts constitute the Core Group. Thereafter, each member of the Core Group involved other experts on this topic with a “snowball sampling” approach.

Sample Size of Panel Members

In literature, it has been suggested that a minimum number of panel members would range from 10 to 18/20 members per area of expertise.^{1–3} Given the six different areas of expertise, we aimed toward a sample size of 60 participants.

Systematic Review of the Literature and Statement Development

The core group had performed a careful review of the literature in his/her own area of expertise, which formed the next steps of the statements building process.

During a brainstorming process, each member of the Core Group submitted a series of relevant statements, based on his/her own expertise area, each with references.

Study Outline

The entire process is summarized in Figure 1, and encompasses two consecutive rounds of consultations.

In Round 1, after the initial identification of a comprehensive list of candidate statements (see Systematic review of the literature and statement development), the coordinating center (University of Trento) contacted the selected panel members (see Section 2.1) and the first voting phase began.

During this phase, participants identified the importance of each statement providing one score per item (nine-point Likert scoring system). Importance was categorized following the OMERACT handbook⁴:

- Score 1–3: the item is not important
- Score 4–6: the item is important but not critical
- Score 7–9: the item is critical

Then, experts were asked to vote their degree of agreement with each item (marking “completely agree,” “partially agree,” “partially disagree,” or “completely disagree”) and, if appropriate, to provide comments or rephrasing.

At the end of this voting phase, results of first Delphi round were analyzed.

First of all, for each statement the frequency distribution of importance was calculated. As suggested in the OMERACT handbook,⁴ statements classified as not important by 70% or more of participants were

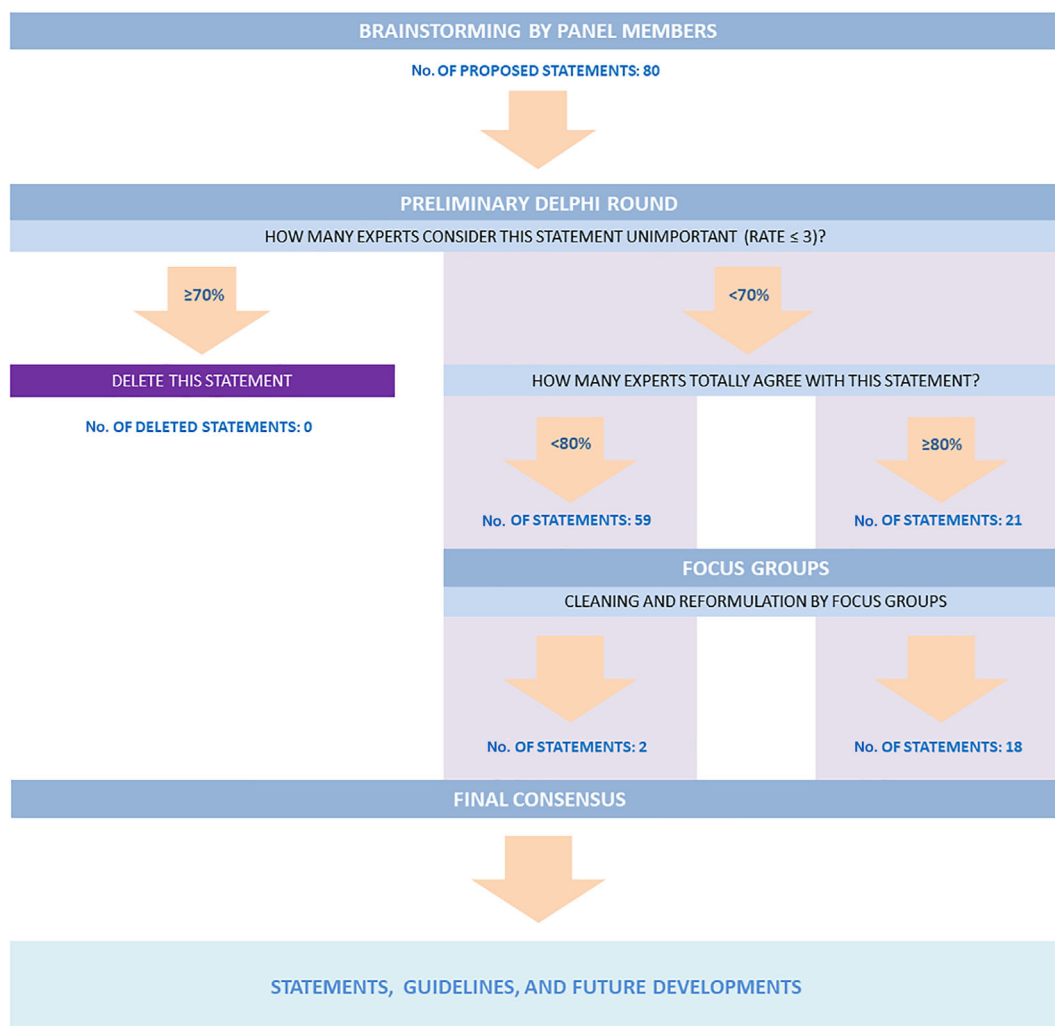
dropped from Delphi process and excluded from the development of final Guidelines. The frequency distribution of importance rate was calculated both for the whole of participants and separately for

Table 1. Summarization of Statements and Guidelines

Statement ID	Statement Classification	Statement Text
1	Technical	As it is already happening in other areas of medical imaging, artificial intelligence (AI) is now being applied to the analysis of LUS data. Critical and well-detailed studies are fundamental to prevent over expectations and misuse of this technology.
2	Technical	Before new technologies will be mature, LUS will continue to be performed with standard ultrasound (US) imaging. In order to improve its reproducibility, standardization of imaging protocols is essential.
3	Technical	In the current definition, B-line artifacts represent a wide variety of patterns. It is crucial to understand the physical origin of their genesis and to characterize the signals responsible for their visualization. This is a fundamental step toward the development of quantitative US modalities dedicated to the diagnosis and monitoring of lung diseases
4	Technical	It is indispensable to find a consensus on objective parameters for the evaluation of regularity/irregularity/thickening of the pleural line and the distinction of micro and macro subpleural consolidations, both for dimensional criteria and for US aspects.
5	Technical	It is necessary to improve the comprehension of the qualitative and quantitative characteristics of the artifacts currently called B-lines in relation to the physiological and pathophysiological changes of histology of the lung.
6	Safety	In animal models, there is evidence that lung ultrasound (LUS) in the diagnostic regime can induce pulmonary capillary hemorrhage. It is therefore required to investigate the need for specific safety limits for US technologies when applied to the monitoring and diagnosis of lung diseases
7	Clinical	There is a need for high quality studies (randomized, prospective) to achieve acceptance for the diagnostic value of LUS as performed for other screening tests (breast, heart).
8	Clinical	There should be evidence and/or consensus for the terminology used to describe artifacts and signs in LUS and for the definition of the extent of the LUS exam.
9	Clinical	It seems reasonable to perform repeated LUS scans to assess the severity of pulmonary congestion, with one and the same probe and protocol each time. Generally, repeated LUS scans can be used for the assessment of the severity of a condition and its progression over time. Always, use one and the same probe and protocol each time.
10	Clinical	LUS should be performed on the largest possible area of the chest that is available during LUS examination (the limitation of the examination area should be justified by the patient's clinical condition).
11	Clinical	LUS has high accuracy in recognition of subpleural consolidation. Subpleural consolidations best known in LUS are: inflammatory lesions, atelectasis, infarction, and metastatic subpleural lesions.
12	Clinical	LUS is feasible and useful in general/family medicine.
13	Clinical	LUS is feasible and useful in prehospital emergency medicine.
14	Clinical	LUS should be used by clinicians as a "point of care" examination in case of patient with dyspnea, chest pain and any chest symptoms.
15	Clinical	The technique of the examination depends on the clinical situation of the patient.
16	Clinical	The functional assessment of the diaphragm may integrate the data of lung alteration to address or refine the differential diagnosis of respiratory failure in intensive care units (ICUs).
17	Clinical	The most common sonographic features in case of pneumonia are: consolidation (with irregular marginal contour, air bronchogram, the air trapping sign), vertical artifacts (B-lines), and the presence of pleural effusion.
18	Educational	It is strongly recommended to acquire adequate training in LUS before its implementation in the diagnostic process.
19	Educational	It is recommended to teach the basis of LUS as part of the students' curriculum.
20	Educational	Remote mentoring of US naive, but motivated and willing first responders has been shown to be a potentially accurate method of generating diagnostic quality ultrasound images that can then be interpreted by remote ultrasound experts.

J Ultrasound Med 2023; 42:309–344

Since it was felt that few statements that reached consensus lacked a specific practical application, a second consultation round was conducted. In Round 2, the coordinating center, after removing redundant items, contacted participants asking to propose 1–3 translations of the general statements in practical guidelines and to add 1–3 “future development” suggestions (also ranked for importance from 1 most important to 3 less important). Web focus groups of



panel members (dedicated to technical, clinical or educational statements) met to further discuss and vote the proposals. Statements that did not meet consensus from the previous round were screened for redundancy or modified by the Core Group according to feedback received in the first round and evaluated again by all participants.

The final list of suggested items approved by each focus group was voted by all participants in a second round by e-mail.

Data Management and CRF

The list of candidate statements has been compiled into a RedCap database,^{6,7} and has been submitted to the evaluation of the whole group of participants with the RedCap survey tool. This database has been developed by Fondazione IRCCS Policlinico San Matteo (Pavia, Italy). Data were collected in non-anonymous form (personalized data) and were hosted at Fondazione IRCCS Policlinico S. Matteo, Pavia (Italy) server.

RedCap database consisted of three sections:

- Section 1: Personal Data (Country, Gender, Age)
- Section 2: Expertise Area and level.
- Section 3: Statements.

Sixty-four experts were invited to respond to Round 1. Among these, 49 (77%) compiled the online form. Thirty-seven (76%) were males, median age was 44 years (IQR: 38–56), 40 (85%) were from Europe and 7 from North America. Eighty-four percent were clinicians and 16% engineers. Sixty-one percent had at least 10 years of experience.

Of initial 80 statements, 21 reached 80% of agreement and after web focus groups 18 were included in the final version of guideline. Two additional statements were derived from the 59 statements that did not reach consensus in the first round (Figure 1).

The 20 statements emerging from the described procedure are listed in Table 1, which also indicates their classification.

Statement 1 (Technical Statement)

As it is already happening in other areas of medical imaging, artificial intelligence (AI) is now being applied to the analysis of LUS data. Critical and

well-detailed studies are fundamental to prevent over expectations and misuse of this technology.

Guidelines—Report the split strategy between test and train data, preferably perform the split at the patient level. Also, report how the frames have been selected, in case not all the available data have been used, and provide details on the scanner and probe used, as well as on the imaging settings (output levels, mechanical index [MI], imaging frequency, focal depth, and imaging depth). Report also all the available clinical information concerning the patients' status, imaging findings, and laboratory test results.

Future Developments—Extensive studies on the impact of the split strategy as well as of the impact of the imaging settings on AI performance are required. Computer-aided solutions should not only focus on the analysis of LUS data. Significant effort should also be focusing on providing real-time feedback aimed at optimizing the quality of the acquired data. AI tools are likely to play a significant role, even more so if used on RF US data, rather than on beam-formed US images. For clarity, the term RF US data refers here to the raw US data, as collected by each element of an US probe, and before the application of the signal-processing operations required to reconstruct an image (eg, band-pass filtering, envelope detection, spatial filtering). In conclusion, AI solutions should also be validated considering not only their technical performance (eg, the ability to identify and segment a given pattern) but also based on their clinical utility (eg, the capability to stratify patients).

AI and machine learning (ML) are increasingly being applied to US images to either segment regions of interest, or provide automated semi-quantitative analysis of images.^{8–10} This is also true in LUS.^{11–14} However, some difficulties remain consistently overlooked in the recent literature. First, ML algorithms are highly sensitive to imaging parameters such as field of view, focal depth and imaging frequency. Second, more careful split strategies, required to separate data used for training and for testing, should be adopted. Large numbers of images have recently been produced in the context of the COVID-19 pandemic.^{15–23} A number of studies have been conducted using AI to extract semi-quantitative parameters out of these images, for scoring and

classification.^{18–24} These parameters or scores have been compared with scores of severity attributed by sonographers and physicians, considered as ground truth, and showed prognostic value.²⁵ Many studies report very high accuracy and sensitivity, suggesting that LUS combined with AI can be extremely useful, at least as a first screening tool in an emergency care setting, or for triage. However, it was demonstrated that splitting strategies had a critical impact on the overall accuracy of the approach.²¹ Unfortunately, many studies still do not report their splitting strategies, or describe their datasets accurately. Many studies also combine images obtained with different US scanners or with different imaging settings, and lump these images to train a single neural network. It is critical that imaging methods, adopted probes and scanners, and splitting strategies are consistently reported in published studies. Additionally, it is necessary to conduct large-scale studies²² with well controlled and consistent imaging parameters, with neural networks trained specifically for a given set of imaging parameters. This will ultimately allow having an understanding of the generalization capabilities (if present) of the algorithms with respect to specific technical aspects.

Beyond image scoring and segmentation, novel AI approaches should also be developed to provide feedback to the user in real time during imaging sessions. There is tremendous potential for AI to help optimize the quality of LUS images as well as to guide the operator during the acquisition.

As an example, to standardize image quality, a proposal explicitly mentioning defined boundaries for key imaging settings (imaging depth, MI, focal-point position, and suggested probes) has been published during the COVID-19 pandemic.²⁴ Moreover, it is important to develop additional criteria on contrast. To do so, the pleural line could be exploited, automatically segmented, and used as a landmark to obtain feedback on image quality. This will contribute to a uniform and reliable assessment of the lung using US.

Finally, AI methods have highly unexploited potential, which could be unleashed if used directly on RF data instead of beam-formed images. This would help exploit the rich information contained in the US signals, which is bound to be affected by structural changes associated with a wide range of lung diseases.

Statement 2 (Technical Statement)

Before new technologies will be mature, LUS will continue to be performed with standard US imaging. In order to improve its reproducibility, standardization of imaging protocols is essential.

Guidelines—In order to guarantee the reproducibility of LUS studies, always report explicitly the adopted MI range, the probe and scanner utilized, the imaging frequency range, the focal and imaging depth range as well as the areas of the chest examined, chest wall thickness and the rationale for the choices made.

Future Developments—Extensive studies are required to define the optimal imaging settings and understand their impact on the imaging patterns.

Growing literature is showing the clinical impact of US imaging for the assessment of lung diseases.²⁶

This is even truer of point-of-care US²⁷ in the context of COVID-19 pandemic.^{28–35}

However, LUS differs from US imaging of other organs and tissues because it lacks one-to-one anatomical relationship between the structure of lung parenchyma and its appearance in the images.³⁶ In fact, the elevated air content of the lung hinders US waves propagation through the parenchyma. In particular, the size and distribution of the air-filled volumes (eg, the alveoli) produces and modulates multiple scattering phenomena, which prevent conventional B-mode anatomical imaging but can be exploited for the assessment of interstitial diseases.^{37–41}

As a result, LUS is still mostly based on the detection and evaluation of imaging artifacts⁴² such as A-lines and B-lines.

Recent studies support the hypotheses that vertical artifacts (B-lines) arise from the propagation of US waves within volumes of lung tissue with reduced aeration that form acoustic traps, ultimately acting as secondary US sources.^{43,44}

Crucially, these artifactual phenomena are highly dependent on the US frequency.^{45–49}

This suggests that LUS findings based on the analysis of vertical artifacts should be interpreted by considering the utilized imaging frequency together with other important imaging settings (pulse bandwidth, focal depth, frame rate, MI, and gain). Moreover, also the appearance of other important LUS

features such as the pleural line, bronchograms, and consolidations does vary with the imaging frequency and bandwidth. In fact, these parameters influence the achievable spatial resolution and can thus provide a different level of detail. Examples of US images displaying typical LUS patterns are shown in Figure 2.

Also, it is relevant to acknowledge the studies on the biological effects connected to acoustic output and scanning time.⁵⁰ It is therefore recommended that clinicians should closely monitor the MI, which is associated with the maximum peak negative pressure generated in the imaging volume, and minimize exposure time. See Statement 6 for more details on safety.

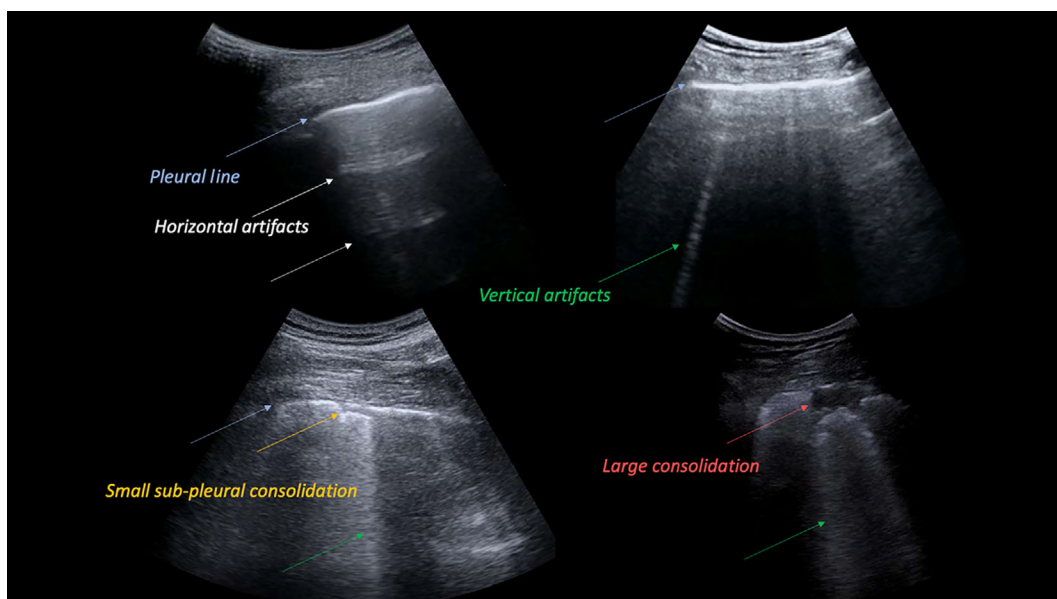
In conclusion, in order to improve lung US reproducibility, standardization of imaging protocols is essential. To this end extended clinical studies providing detailed information on the adopted MI range, probe and scanner utilized, imaging frequency and bandwidth, focal and imaging depth range as well as the areas of the chest examined, chest wall thickness, and the rationale for the choices made, are needed. These studies will also allow to understand and possibly characterize the variability of the most important lung US imaging patterns as a function of the adopted imaging parameters.

Statement 3 (Technical Statement)

In the current definition, B-line artifacts represent a wide variety of patterns. It is crucial to understand the physical origin of their genesis and to characterize the signals responsible for their visualization. This is a fundamental step toward the development of quantitative US modalities dedicated to the diagnosis and monitoring of lung diseases.

Guidelines—In order to guarantee the reproducibility of LUS studies, always report explicitly the adopted MI range, the probe and scanner utilized, the imaging frequency range, the focal and imaging depth range as well as the areas of the chest examined, chest wall thickness and the rationale for the choices made. LUS image analysis could include the investigation of pleural effusion (not an artifact), characterization of the pleural line (not an artifact) and consolidations (not an artifact), as well as, the study of vertical artifacts (eg, B-lines, white lung), horizontal artifacts (A-lines), and pleural motion. Acknowledge that the appearance of LUS artifacts is operator dependent. Refer to B-line counting as a semi-quantitative method as that is not an absolute measure but a relative and operator-dependent measure. To the same extent, any qualitative characterization of LUS artifacts concerning their

Figure 2. Examples of ultrasound images displaying typical LUS patterns. Pleural line, horizontal artifacts (A-lines), vertical artifacts (B-lines), and consolidations are indicated by blue, white, green and red arrows, respectively.



length, image intensity and appearance should always acknowledge the impact of the utilized hardware and imaging settings on these properties.

Future Developments—In order to enable clear distinctions between qualitative and quantitative features, clinical studies detailing the adopted hardware and imaging settings are needed to correlate LUS imaging findings (pleural effusion, consolidation, A and B lines, white lung, pleural line alterations) with patients' conditions and diagnosis. In order to develop quantitative methods, studies are needed which investigate the appearance of LUS imaging artifacts as a function of the adopted hardware, imaging parameters, and lung microstructure. This should include clinical studies, as well as in vitro and large animal studies, with known ground truth on the microstructure (obtained by CT or histology). Additionally, numerical studies could be used to gain insights on US propagation in lung tissue.

B-line artifacts represent one of the most significant artifacts in LUS. A correlation exists between B-lines and many lung diseases including increased extravascular lung water,⁵¹ interstitial lung diseases,⁵² cardiogenic and non-cardiogenic lung edema,⁵³ interstitial pneumonia,⁵⁴ lung contusion,⁵⁵ and COVID-19.²⁴

According to the first international consensus conference on LUS, B-lines were defined as “discrete laser-like vertical hyperechoic reverberation artifacts that arise from the pleural line (previously described as ‘comet tails’), extend to the bottom of the screen without fading, and move synchronously with lung sliding.”⁵⁶

The practical use of this definition poses however several challenges, and limits the accuracy and reproducibility of the associated evaluations. Many aspects of this definition are highly subjective. It is difficult to associate quantitative information with the words “laser-like” and “without fading.” Reproducible methods to evaluate the lateral extent of artifacts have not been established. It is likely that by varying the imaging depth, the artifact will no longer reach the “bottom of the screen,” and there is no defined minimum length for the vertical artifact to be referred as a B-line. Moreover, the impact of key imaging parameters (frequency, bandwidth, beam width, angle of incidence, dynamic range) on the appearance of B-lines is not accounted for in this definition.⁵⁷

This needs to be addressed if we are to develop a reproducible, accurate, and reliable US method dedicated to the lung. Additionally, standardization of the acquisition process is essential to minimize the effect of confounding factors.

Starting from the discussion on the underlying physical mechanisms involved in the formation of B-lines,^{26,39,42,43,58} to the first numerical,^{46,59} in vitro^{44,47,48,60,61} and clinical studies,^{49,62,63} several publications have shed light on the subject.

It has clearly emerged from numerical,⁴⁶ experimental,^{44,47,48} and clinical data^{49,58,63} that the imaging frequency and the bandwidth play a major role in the visualization of B-lines (now generally referred to as vertical artifacts). Indeed, while imaging the very same point of the lung surface several vertical artifacts may be visualized, or none at all, depending on the adopted imaging frequency. This is confirmed by clinical LUS data acquired with both commercial and research US scanners.^{49,58,63} The position of the focal point (which should preferably be located at the pleural-line) and the angle of incidence are also determining factors in the appearance of vertical artifacts, although of less significance.⁴⁸ In experimental models, no correlation was found between the beam width and vertical artifacts intensity.⁴⁷

It is thus clear that B-line counting can be at best referred to as a semi-quantitative method, given the strong dependency of B-lines visualization on the adopted hardware and imaging settings.

Regarding the understating of the genesis of vertical artifacts, the formation of acoustic traps along the lung surface is the most convincing hypothesis. These traps can form in connection with a large variety of pathologies, and are due to the replacement of lung volumes originally occupied by air with media acoustically similar to the intercostal tissue (eg, water, blood, scar tissue). This replacement opens channels accessible to US, which can act as a secondary source of US fields by effect of multiple scattering. Moreover, resonance phenomena are the most-likely explanation for the strong dependence of vertical artifacts on the imaging frequency and bandwidth.^{44,46–49,63} This opens the possibility to characterize the alterations along the lung surface (the trap geometry and content) by means of quantitative US spectroscopy. The first clinical pilot study showed (on 26 patients) the ability of this type of analysis to discriminate

patients suffering from fibrosis from those affected by other lung diseases.⁶³

Statement 4 (Technical Statement)

It is indispensable to find a consensus on objective parameters for the evaluation of regularity/irregularity/thickening of the pleural line and the distinction of micro- and macro-subpleural consolidations, both for dimensional criteria and for US aspects.

Guidelines—Report the details on the spatial resolution of the imaging system and implement quantitative instead of qualitative characterizations, that is, provide the actual size in millimeter rather than qualitative descriptions (“small,” “large,” or similar).

Future Developments—Extensive studies are required to determine the cut-off sizes which may define the relevance of the different findings.

The recent experience on COVID-19 has underlined the importance of the correct US evaluation of the pleural-line and of the subpleural space in the definition of infectious diseases involving the lung.^{24,28}

It was already known that numerous pathologies involving the lung (eg, ARDS, fibrosis, interstitial lung disease in rheumatic pathologies, pneumonia, inhomogeneous pleural edema) can lead to the development of pleural irregularities and/or subpleural space geometry and air/solid ratio alterations, which are observable in US images as pleural-line irregularities, nodulations, and micro- or macro-consolidations.^{39,64}

Currently, even after the advent of COVID-19, the US analysis of the pleural-line and subpleural space is mostly limited to a qualitative, subjective, not measurable or reproducible evaluation. There is a lack of evidence in the scientific literature regarding a clear definition and measure of regularity/irregularity/thickening/fragmentation of the pleural line or of the dimensional and quantitative distinction between subpleural micro- and macro-consolidations.^{56,65}

Furthermore, no decisive studies have been produced that investigated the possible different meaning of these US findings according to the physical and histological variations of the lung involved in the different diseases.^{66–68}

In recent years, we have seen the publication of the first studies in which clinical research concerning the analysis of the pleural-line and subpleural space

has been integrated with computer-aided solutions.^{19,69–71} These seem to be the first steps in the right direction, as these methodologies can improve the reproducibility of the analysis. However, there remains the need to implement large clinical studies focused on quantitative rather than qualitative or semi-quantitative methods. The goal of these studies should be the definition of objective and reproducible measures capable of describing the dimensions of specific US anatomical patterns (pleural-line, consolidations) and their correlation with the clinical findings. These studies must necessarily be rigorous from a technical point of view. In this respect, studies should report the details of the imaging system, including the adopted probe, imaging frequency, location of the focal point, MI values when available, and indicate the spatial resolution (lateral and axial) obtained at the focal point. The latter can be easily derived from imaging a wire target immersed in water⁴⁷ and it is fundamental to understand the accuracy of the employed imaging system at representing spatial changes in the imaging volume.

In conclusion, large studies are needed to determine the cut-off dimensions (expressed in mm) that can define the relevance of the different findings related to the analysis of the pleural-line and subpleural space appearance in relation to the different pathological state of the lung. This analysis will have to be integrated with the results derived from studies on numerical,^{46,59} in vitro⁴⁷ and in vivo experimental models,⁷² possibly adopting standardized acquisition methods as well as computer-aided solutions supporting and facilitating the analysis of the data. Correlation of these results with the histological findings should also be investigated.⁷³

Statement 5 (Technical Statement)

It is necessary to improve the comprehension of the qualitative and quantitative characteristics of the artifacts currently called B-lines in relation to the physiological and pathophysiological changes of histology of the lung.

Guidelines—In order to guarantee the reproducibility of LUS studies, always report explicitly the adopted MI range, the probe and scanner utilized, the imaging frequency range, the focal and imaging depth range as well as the areas of the chest examined, chest wall

thickness and the rationale for the choices made. LUS image analysis could include the investigation of pleural effusions (not an artifact), characterization of the pleural line (not an artifact) and consolidations (not an artifact), as well as, the study of vertical artifacts (eg, B-lines, white lung), horizontal artifacts (A-lines) and pleural motion. Acknowledge that the appearance of LUS artifacts is operator-dependent. Refer to B-line counting as a semi-quantitative method as that is not an absolute measure but a relative and operator-dependent measure. To the same extent, any qualitative characterization of LUS artifacts concerning their length, image intensity and appearance should always acknowledge the impact of the utilized hardware and imaging settings on these properties.

Future Developments—In order to be capable of clearly distinguishing between qualitative and quantitative features, clinical studies detailing the adopted hardware and imaging settings are needed to correlate LUS imaging findings (pleural effusion, consolidation, A and B lines, white lung, and pleural line alterations) with patients' conditions and diagnosis. Moreover, to develop quantitative methods, studies are needed which investigate the appearance of LUS imaging artifacts as a function of the adopted hardware, imaging parameters and lung microstructure. This should include clinical studies, as well as in vitro and large animal studies, with known ground truth on the microstructure (obtained by CT or histology). Additionally, numerical studies could be used to gain insights on US propagation in lung tissue.

Recent studies extensively demonstrated how key parameters such as the imaging frequency significantly influence the visualization of vertical artifacts. This implies that the very same patient, if assessed based on the counting of vertical artifacts, may be evaluated differently depending on the adopted US probe, imaging settings and systems. A truly quantitative method can be defined as such as long as it is based on objectively measurable quantities.

As an example, the quantitative frequency-characterization of the US signals responsible for the generation of B-lines has proven that

1. the very same structure produces or not vertical artifacts depending on the employed center frequency and bandwidth;

2. vertical artifacts native frequency and bandwidth can be exploited to characterize the subpleural space, and improve LUS specificity.

These studies demonstrated the potentials of specific US methods dedicated around the properties of the lungs, and pointed out the limitations of LUS if confined to the subjective and visual interpretation of imaging artifacts.^{43,44,47,49,57,63}

Studies on controllable experimental models are essential for deepening our understanding of the links between the characteristics of the artifacts and the geometrical and acoustical properties of the structures responsible for their generation.

Lungs have a fractal nature. The fundamental unit, the alveolus,⁷⁴ is repeated n -times to cover, with maximal effectiveness, in terms of surface for gas exchanges, the whole space available in the chest cage.⁷⁵ The surface of this frothy⁷⁶ and fractal substrate, in normal inflated conditions, acts like a mirror for USs, hampering the morphological assessment beyond the pleural plane. Peripheral airspace geometry behaves in this case as a barrier and no irregularities can be seen by common wavelengths used in diagnostics.³⁹

A vertical artifact can be produced in every point of the pleural surface in which the normal specular reflector is interrupted. In this way, US waves can sense, in relation to their wavelength, a structure with reduced impedance mismatch (a kind of "acoustic micro-hole"), that might also be capable of trapping US waves within a highly reflective interface. Numerous configurations have been studied as potential acoustic traps and many mechanisms may act together.^{26,77} The common denominator is however the increase in the full-to-empty ratio of lung tissue immediately beneath the pleural-line and therefore, the changes in peripheral geometry and connectivity of airspaces which lastly means peripheral subpleural histopathology of lungs.

Several studies demonstrated how vertical artifacts can be reproduced synthetically investigating foams of wet polyurethane or bubbles.^{43,44} In particular, single and double layers of bubbles floating on a water surface were able to generate vertical artifacts only in specific conditions, with double layers and bubble radius representing critical factors for the visualization of vertical artifacts. These studies further

demonstrated the impact of the geometric disposition of the air spaces.^{55,76}

Moreover, three-dimensional (3D) reconstructions of lung tissue show a frothy nature similar to that of common foams.⁷⁸ This could explain why porous wet polyurethane can generate sonographic interstitial syndrome as well.

Vertical artifacts are thus the visual representations of the signals originating from the multiple scattering of US waves when trapped inside the channels that are formed between the air spaces. The acoustic trap configuration and volume as well as its shape, its content and the dimensions of its entering channel are variable and depend on the pathology. Thus, it is not surprising that vertical artifacts look different for different diseases and at different stages of a specific disease.⁴²

Ordered, regular and aqueous acoustic traps in early cardiogenic sonographic interstitial syndrome could thus be characterized by specific spectral signatures, different from irregular, fibrotic, and disordered ones as present in primary pneumogenic pathologies.^{38,42,43,63} These hypotheses may also explain why vertical artifacts can vary so significantly, and even appear or disappear, depending on the imaging frequency.^{44,49}

In conclusion, the quantitative frequency-characterization of vertical artifacts appears to be one of the most promising approaches to be exploited for the quantitative analysis of vertical artifacts and for the development of a non-invasive US method for the characterization of the lung surface, with results already reported from numerical,⁴⁶ in vitro,^{44,47} and clinical studies.^{49,63}

In order to develop quantitative methods, further and larger clinical studies are needed which investigate the appearance of LUS imaging artifacts as a function of the adopted hardware, imaging parameters, and lung microstructure. This should include clinical studies, as well as in vitro and animal studies, with known ground truth on the lung microstructure (obtained by CT and/or histology). Additionally, numerical studies could be used to gain insights on US propagation in lung tissue.

Statement 6 (Safety Statement)

In animal models, there is evidence that LUS in the diagnostic regime can induce pulmonary capillary

hemorrhage. It is therefore required to investigate the need for specific safety limits for US technologies when applied to the monitoring and diagnosis of lung diseases.

Guidelines—As of today, there is no significant bioeffect for diagnostic LUS reported in humans. However, LUS providers should be aware that LUS is not absolutely without risk of harm. In animal models, there is evidence that LUS in the diagnostic regime can induce PCH. The likelihood of this event appears to increase with exposure time, MI, and temporal output power (Doppler). The clinical significance in humans is unknown. We recommend that the ALARA principle should be applied.

Future Developments—Detailed and extensive studies are needed to define an international consensus on the safety limits for LUS in patients.

As shown in animal model research, LUS in the diagnostic regime can affect the alveolar epithelium–gas interface. Therefore, a potential exists for microvascular PCH injury with clinical LUS and for confounding of LUS diagnosis by introduction of extraneous occurrence of the B-line sign. The clinical significance in humans remains uncertain, because it has not been investigated on a pathological level as in animal studies. Therefore, the application of mitigating guidance based on animal models is prudently recommended during human LUS.

Clinician and LUS providers should be aware that LUS is not absolutely without risk of harm from the diagnostic US exposure. The high diagnostic value of a non-ionizing sonographic lung imaging modality correctly applied in clinical practice provides substantial patient benefit.^{39,64,79,80} However, non-clinical research in animal models has demonstrated that LUS in the diagnostic regime can induce pulmonary capillary hemorrhage (PCH). The likelihood and magnitude of this bioeffect, above an acoustic output threshold dependent on the specific details of the case, increases with increasing exposure duration and output indicated by the MI, or output power (pDoppler, SWE). There is negligible risk of PCH for outputs below a worst-case threshold of $MI = 0.4$.⁸¹ The sonography induced PCH was shown to be limited to subpleural tissue to a maximum depth of a few mm and is related to the size of the transducer. Any

diagnostic LUS induced PCH is expected to be asymptomatic, does not represent alveolar rupture and does not require interventions.^{82,83} Diagnostic concerns arise due to the fact that PCH can mimic LUS signs (B lines and white lung) and therefore may influence the diagnostic outcome.^{84,85}

Several sonographic societies such as AIUM, BMUs, and recently EFSUMB recommend the use of lung sonography depending on exposure time not to exceed a MI >0.4 – 0.7 .^{86,87} In obese patients, PCH is much less likely to occur during LUS due to high attenuation of intercostal tissue.⁸⁸ The use of the ALARA principal is strongly recommended whenever LUS is performed above the recommended MI. Reducing exposure output and scan duration, independent of mode, significantly decreases the likelihood of PCH induction and its extent.^{85,89} A LUS specific Pre-Set should be used when provided by the scanner. Such Pre-Sets are optimized for imaging aspects and vary over a wide acoustic output range. Therefore, before examination, the lung settings should be setup and stored with an initial MI < 0.4 and this should only be increased in case of imaging needs.

The poorly defined guidelines for LUS based on the output power settings (eg, MI) and scan duration require further investigation for development of specific safety limits for US technologies when applied to the monitoring and diagnosis of lung diseases. To this end a specific Lung Safety Index including TI, MI and other pertinent parameters should be investigated in future studies.^{81,89}

Statement 7 (Clinical Statement)

There is a need for high quality studies (randomized, prospective) to achieve acceptance for the diagnostic value of LUS as performed for other screening tests (breast, heart).

Guidelines—Perform LUS on the largest possible area of the chest that is available during a LUS examination.

Limitation of the area (field, region) examined may be justified by the patient's clinical condition (trauma), limited accessibility, other practical aspects such as the capability to cooperate, and chest condition (scars, obesity).

Future Developments—Conduct extensive high-quality prospective studies to elicit the contribution of LUS to define its role in different lung conditions.

Numerous meta-analyses have been published that reported the high diagnostic accuracy and usefulness of LUS in the diagnosis of pneumothorax, pulmonary edema, fibrosis secondary to interstitial lung disease, and pneumonia in adults, children, and neonates.^{56,90–97}

Moreover, recommendations for the use of LUS, including its application as a point-of-care method in intensive care and in the pediatric population, are available.^{56,98–100} Some of these publications offer evidence to the accuracy of LUS diagnostic potential in particular lung diseases, while other simply propose recommendations.

However, large, multicenter prospective and randomized studies performed on patients in various age groups and depending on patients' clinical conditions, including (eg, ambulatory patients, pediatric patients, patients in internal medicine departments or intensive care units) are currently lacking. Analogously, randomized studies devoted to the application of LUS in the monitoring of various lung diseases in different age groups and clinical categories are also limited.

The adopted LUS methodology depends on many factors, for example, the patient's clinical condition, age, body structure, and current condition (chest deformation, obesity, dressings ...). Despite the narrowing and precise determination of patient groups, LUS examinations are performed differently worldwide as regards the assessment modality (eg, with a different amount and location of the scanned areas on the chest) and technical aspects (eg, with different transducers and settings of US devices).

These differences also depend on the clinical settings, for example, intensive care versus pneumology. Consequently, the comparability of results across different studies is reduced, and only few studies comparing different protocols are available.¹⁰¹

Moreover, another critical point is that the reference standard in accuracy studies concerning LUS is computed tomography (CT), which extensive use for prospective studies is often restricted by Ethical Committees due to radio-exposure. This is particularly true in those groups of patients (ie, pregnant women, pediatric population) which may benefit from a more extensive use of LUS.

Future studies should promote the cooperation of specialists from different fields and medical centers, including technical and clinical expertise, and focusing on randomized studies involving large cohorts.

Statement 8 (Clinical Statement)

There should be evidence and/or consensus for the terminology used to describe artifacts and signs in LUS and for the definition of the extent of the LUS exam.

Guidelines—Use standardized terminology to describe artifacts and signs in LUS based on current or future dictionaries (eg, vertical artifacts [B Lines]/confluent B line/white lung syndrome, pleural thickness [mm], pleural irregularities, horizontal lines [A-lines]).

Future Developments—Develop a common ontology (dictionary) to be used to standardize reporting of LUS findings and measurements of diaphragm function. Include supportive images and videos. Promote and develop studies to better understand the mechanism of LUS interaction with lung tissue and of artifacts generation and meaning. Promote studies for the definition of safety indices in LUS examination.

Over the past three decades, various respiratory pathophysiological conditions have been shown to alter the acoustic properties of the lung, thus making it accessible for US exploration.^{26,27,36–39,102}

Going beyond its established role in the management of pleural effusion,¹⁰³ US has been widely applied in the approach to the patient with various pleuropulmonary conditions, such as pneumonia,^{104–107} pneumothorax,^{108–111} cardiogenic and non-cardiogenic pulmonary edema,^{53,95,112,113} acute respiratory distress syndrome.^{64,114–118} Furthermore, US can be used to study diaphragmatic function.^{119–121}

Yet, despite a wide use of the technique, there is a need for consensus for the terminology used to describe LUS artifacts and signs.

A lines and B lines are two separate and distinct artifacts which can be found as a consequence of acoustic interactions with the lung surface during US examination.

Horizontal artifacts, commonly referred to as “A lines,” are hyperechoic horizontal lines that appear parallel to the pleural line, which represents how the intercostal–tissue to lung–surface interface is

visualized on LUS images. In this sense, the pleural line does not fully coincide with an anatomical representation of the pleura but cannot be considered an artifact as it still represents an anatomical landmark. A lines are equidistant from each other and their depth is equal to multiples of the distance between the probe and the pleural line. Horizontal artifacts can be found in normal peripheral US patterns, states of pulmonary over-distension, and in the case of pneumothorax (in this latter case, US diagnosis will also be supported by the absence of sliding of the pleural line and by the finding of the lung point^{122–124}). The genesis of horizontal artifacts is well known. They can be in fact associated to reverberation phenomena occurring between the probe and the lung surface.^{125,126}

In the last consensus (2012) the vertical artifacts, commonly referred as “B lines,” were originally defined as discrete laser-like vertical hyperechoic reverberation artifacts which arise from the pleural line, extend to the bottom of the screen without fading and move synchronously with lung sliding.⁵⁶

Despite the widespread use of vertical artifacts for identification and monitoring of different pleuropulmonary pathophysiological conditions,^{91,127,128} we currently do not fully understand the origin of this acoustic information.³⁹

Furthermore, vertical artifacts appearance differs greatly, depending on the subpleural pathophysiological lung status,^{36,38} on the US pulse center frequency and bandwidth, and on the shape of the probe (which influences the angle of incidence).^{36,38,43,44,47,49,55,63,129}

Multiple or confluent vertical artifacts can be referred to as sonographic lung interstitial syndrome.⁵⁶ Finally, the “white lung” term is generally used to describe a lung field without horizontal artifacts and of a noise-like appearance.

Sonographic interstitial syndrome can be classified on the basis of its extent over the lung surface, as focal or diffuse.⁵⁶ In case of diffuse and bilateral extension, it is useful to distinguish whether vertical artifacts have a homogeneous or heterogeneous (ie, with spared areas) appearance, and to evaluate if they show a gradient of concentration in the apical–caudal or ventral–dorsal sense.⁵³

Finally, it is useful to evaluate pleural line abnormalities. These include irregular, fragmented, and thickened pleural line.^{39,53,56,95,112–115,128}

To standardize the reporting of LUS findings, a common ontology (dictionary) needs to be developed. Furthermore, large clinical studies including the use of US research platforms are needed to understand and characterize the US signals associated with the generation of vertical artifacts. These studies have in fact the potential of improving the reproducibility and diagnostic specificity of LUS.

Statement 9 (Clinical Statement)

It seems reasonable to perform repeated LUS scans to assess the severity of pulmonary congestion, with one and the same probe and protocol each time.

Generally, repeated LUS scans can be used for the assessment of the severity of a condition and its progression over time. Always, use one and the same probe and protocol each time.

Guidelines—Perform a complete scan of the thorax, specifically on a plane from the xiphoid-sternal line to the mid-clavicular, mid-axillary, and posterior-axillary lines. Partial examination may be performed depending on the condition of the patient.

In the case of cardiogenic pulmonary edema, use a center frequency of 5–6 MHz, gain up to 50%, depending on patients' features, without harmonic imaging. Convex or linear probes may be used. These settings may apply to other conditions with a similar clinical presentation. In patients with exercise dyspnea and heart failure, it is recommended to repeat the US examination of the lungs during the exercise test.

Report the spatial distribution of the vertical artifacts/B-lines

- Homogeneous/heterogeneous
- Focused/bilateral
- With/without gravitational gradient

Future Developments—Obtain information from high quality large studies to define optimal time intervals at which LUS should be repeated for monitoring in specific clinical situations.

The possibility to assess pulmonary congestion and cardiogenic pulmonary edema by LUS is well-documented.^{130–134} When evaluating pulmonary edema, B-line artifacts, their number, gravitational gradient and bilateral occurrence can be qualitatively analyzed by visual analysis of the US clips. The term “interstitial syndrome,” indicating the presence of

fluid in the interstitial space, has been proposed (be aware of the non-specificity of interstitial syndrome for the diagnosis of pulmonary edema as interstitial space density can be altered not only by fluid increase but also by others pathological conditions, eg, collagen deposition). Interstitial syndrome has been defined by the presence of multiple B-line artifacts in a single scan (be aware that number of vertical artifacts can vary depending on machine type and settings, frequency and incidence angle used. See technical statements). The appearance of these patterns can be linked to the increase of fluids in the interstitial space. In fact, fluid may seep into alveoli, filling them to various degrees. During an US assessment, two signs are searched for: the alveolar-interstitial syndrome (AIS) and white lung that, respectively, indicate a more advanced involvement that is secondary to the progression of pulmonary edema. In the US assessment of patients with pulmonary edema, attention is also paid to the regularity of the pleural line and its continuity, as the presence of irregular pleural line together with vertical artifacts must lead to think to an overlap of pneumogenic pathological condition. Pleural effusion may be a co-occurring sign.^{135,136}

LUS is considered to be very helpful for the monitoring of patients with pulmonary edema in a hospital setting. In patients hospitalized due to cardiogenic pulmonary edema, correlation has been reported between the number of B-lines and the NYHA functional class, NT-proBNP level, and other echocardiographic parameters.^{137–139} The applicability of LUS for the ambulatory monitoring of patients with congestive heart failure have also been documented, with positive effects on the reduction of hospitalizations reported.¹³⁸

Statement 10 (Clinical Statement)

LUS should be performed on the largest possible area of the chest that is available during LUS examination (the limitation of the examination area should be justified by the patient's clinical condition).

Guidelines—Perform LUS on the largest possible area of the chest that is available during the examination.

Limitation of the area (field; region) examined may be justified by the patient's clinical condition, limited accessibility and other practical aspects, such

as patient capability to cooperate, chest condition (scars, obesity).

Future Developments—Design studies to assess the diagnostic accuracy of LUS based on the available evidence for each disease/setting of application, using an appropriate gold standard.

Harmonize specific protocols by disease/setting of use, such as lung congestion, pulmonary embolism, subpleural consolidation, ICU patient, and athlete after exertion by describing

- the image acquisition protocol (including the imaging settings);
- the typical LUS patterns w.r.t. the specific disease/setting.

In the first clinical applications, LUS protocols were kept simple and focused on rapid differential diagnosis of the causes of acute respiratory failure (eg, the BLUE-protocol).¹⁴⁰ It was in fact assumed that the lungs were such a large organ that pathologies causing acute respiratory failure should be extensive and easy to visualize. Indeed, when not affecting the results of the evaluation, a rapid LUS acquisition protocol should be favored as it reduces both the time needed to perform the exam as well as the time required to analyse the data (independently on the fact that the analysis is conducted by a human operator or by an automatic system^{18–20}).

In specific clinical situations, the use of rapid protocols remains justified. They seem to be particularly useful in emergency medicine or as a tool for rapid differential diagnosis of the causes of shock (FALLS-protocol) or sudden cardiac arrest (SESAME-protocol).^{140–142} In these cases, the versatility of the micro-convex probe comes at hand, allowing for a quick initial assessment of the lungs, the heart, the large blood vessels and abdominal cavity.^{140–142}

In the assessment of patients hospitalized at the ICU, the LUS Score is one of the most wide spread, assessing four consecutive stages of lung aeration loss (N, B1, B2, C) based on the assessment of six areas on each side of the chest (anterior, lateral, and posterior fields are identified by sternum, anterior, and posterior axillary lines; each field is divided into superior and inferior regions).¹⁴³ However, in studies assessing the degree of fluid overload in dialysis patients, 28 scan protocols (16 scans from the right half and

12 scans from the left anterolateral surface of the chest) are used and the number of B lines (B-line score) is generally reported.¹⁴⁴ In studies of patients with chronic and acute heart failure, protocols of 8, 6, and 4 scans have been proposed.^{130,143,145–147}

A common feature of the “cardiology” protocols is the omission of the posterior surface of the chest (which may be their certain weakness). Experience with LUS in assessing COVID-19 patients shows, however, that the alterations visualized in the posterior areas are the most significant.¹⁰¹ Assessing each intercostal space along its entire length is time-consuming, so reasonably simplified protocols have been suggested for COVID-19 patients as well, such as 18^{58–55,57–151} and 14 scan protocols.^{24,101} Lately one interesting study on the correlation between LUS and laboratory results also described a protocol of 12 scans (quick COVID-19 severity index [qCSI]), 6 for each half of the chest (upper and lower areas of the anterior, lateral and posterior surfaces, respectively), for assessing the presence of B-line and/or consolidation.¹⁵² Other studies also opted for a 10 scans protocol.¹⁵³

Moreover, a recently published multicenter study, which compared the performance of different acquisition protocols with respect to their capability to intercept the most important findings for COVID-19 and post-COVID-19 patients, also reports a 12 scans protocol (6 for each half of the chest) as the optimal trade-off between rapid and accurate evaluation.¹⁰¹

In general, when describing the results of a LUS study, it should be always specified whether the examination was performed according to one of the protocols described above, or whether each successive intercostal space was assessed on the entire surface of the chest. As previously discussed, be aware that counting of vertical artifacts should be considered at best as a semi-quantitative approach. In fact, beyond the obvious difficulties in defining unambiguously what should be considered a vertical artifact and what not, the appearance of these patterns is strongly dependent on numerous technical parameters (see technical statements). Consequently, the reproducibility of these methodology is considered to be poor and the comparison across different studies not feasible.

A complete examination should be performed in stable patients as part of the diagnosis of chronic diseases.

The development of research using LUS protocols adapted to specific clinical situations may lead to standardized protocols that are optimized for specific diseases. Moreover, for the sake of the study reproducibility, the employed scanner type and probes, as well as the adopted imaging settings (focal point position, imaging frequency, and MI) should also be always reported.²⁴ Indeed, the visualized LUS patterns can change significantly based on the employed imaging solutions, as described in details in the technical statements section.

Statement 11 (Clinical Statement)

LUS has high accuracy in recognition of subpleural consolidation. Subpleural consolidations best known in LUS are: inflammatory lesions, atelectasis, infarction, and metastatic subpleural lesions.

Guidelines (Specific for Pneumonia)—Whenever possible, use contrast enhanced LUS evaluations to obtain further information about peripheral consolidations.

Guidelines (General)—LUS may be used as a diagnostic tool for the recognition of subpleural consolidation, alone or to complement other imaging techniques.

The study of subpleural consolidations should be carried out with the combined use of convex and linear probes given the well-known accuracy of LUS in identifying subpleural lesions of inflammatory, infarct, neoplastic or atelectatic nature.

If the size of the consolidation allows it, use contrast enhanced LUS evaluations to obtain further information about the characterization of the peripheral consolidations.

Future Developments

Harmonize specific protocols by disease/setting of use, such as lung congestion, pulmonary embolism, subpleural consolidation, ICU patient, and athlete after exertion by describing

- the image acquisition protocol (including the imaging settings);
- the typical LUS patterns w.r.t. the specific disease/setting.

Following an inflammatory event, airways collapse, neoplasm, or alveolar flooding, lungs lose their normal inflated structure and reduce their air content. In these circumstances, as the air spaces of the lung are substituted and/or filled with fluids or soft tissue,

“lung hepatization” occurs. From the radiological point of view, this condition corresponds to radiopaque lung consolidation.¹⁵⁴

Lung consolidations can be detected by LUS, although only in case of direct contact with visceral pleura. Subpleural consolidations can be of diverse nature: atelectasis, inflammatory, infarctual, contusive and neoplastic. LUS can be considered a useful diagnostic tool for the detection of subpleural consolidation, alone or to complement other imaging techniques.¹⁵⁵ See also statement 17 for large inflammatory lung consolidations (pneumonia).

For subpleural consolidations, the use of contrast enhanced ultrasound (CEUS) could support the acquisition of relevant clinical information, although its utility is still debated.^{156–160}

Generally, the size of the consolidation seems to be decisive.¹⁵⁷

When using CEUS, the investigated features are the “time to enhancement” (TE) and “extent of enhancement” (EE).^{154,155}

TE represents the time interval between the intravenous injection of contrast agents and the intensity enhancement of the consolidated area on the CEUS clip.¹⁶¹

Pulmonary artery vascularization determines the appearance of contrast enhancement (CE) within 6 seconds from infusion (early TE). The appearance of CE after this time is indicative of bronchial arteries vascularization (late TE).

Furthermore, CE can be characterized as spatially homogeneous or heterogeneous.

Consolidation EE (marked or reduced) is usually evaluated in relation to the enhancement of the spleen parenchyma.

Inflammatory and atelectatic consolidations show early TE and marked EE. CE is homogeneous. Differently, pulmonary infarction is characterized by the absence of CE.

Significant experiences have been also reported on the use of CEUS imaging in case of post embolic subpleural consolidations of the lung.^{162–164}

Moreover, neoplastic lesions show variable behavior and the utility of CEUS in this context is currently debated.^{158,159} Generally, they present late TE and variable EE with heterogeneous CE. However, variations in the TE have been reported in case of adenocarcinomas.¹⁵⁹ Necrotic areas do not present CE.

Interesting experiences have been reported also in the context of subpleural consolidation characterization in COVID-19 patients.^{68,165} These experiences have demonstrated that, at least in part, some consolidations have been caused by perfusion defects and ischemic phenomena, and not only by atelectasis and inflammation, thus endorsing the ever grooving key role of thromboembolic disorders in cases of COVID-19 pneumonia with severe respiratory failure.¹⁶⁶

Further studies are needed to better define the use of CEUS for subpleural lesions characterization, to standardize the exam conduction, and to define specific technical requirements.

Statement 12 (Clinical Statement)

LUS is feasible and useful in general/family medicine.

Guidelines—It is possible to use LUS for obtaining thoracic signs, especially in case of pleural effusion, interstitial syndrome, pulmonary consolidation, pneumothorax, or other conditions.

Future Developments—Investigate to use LUS as first line diagnostic tool for monitoring of disease/conditions such as pleural effusion, chronic heart failure, and community acquired pneumonia.

The primary care physician/general practitioner (GP) in his/her office has limited diagnostic possibilities and often finds himself/herself in a situation where the medical history and physical examination need to be supplemented with additional examinations, including imaging examinations.^{167–169} Point-of-care US in the GP office is enjoying increasing popularity.^{170–172} The use of LUS at the stage of outpatient diagnostics is beneficial for not only the patient and physician, indeed given its cost-effectiveness it should also be viewed in light of its potential for health care system costs reduction.^{173–175} Numerous examples of the use of US in the diagnostics of adults and children in outpatient treatment and even during home visits have been described.^{176–183} The use of US in the GP office reduces the time to make an accurate diagnosis, helps in making therapeutic decisions and may improve the patient's prognosis.^{184,185} Moreover, LUS used as point-of-care examination method may reduce proportions in the quality of medical services depending

on the place of residence and reduce the costs of patient care.^{185–187} In everyday practice, LUS can provide support for a quick differentiation of the causes of such common symptoms as dyspnea or cough. The main pathologies that can be quickly assessed with LUS are pleural fluid, cardiogenic or non-cardiogenic pulmonary edema, subpleural consolidation in the course of pneumonia, and pneumothorax.^{90,93,104,106,177,188–201} Compared with the classic physical examination, LUS is characterized by greater accuracy in the assessment of changes in the course of lower respiratory tract infection and the presence of fluid in the pleural cavities.^{188,202} Moreover, compared with classic imaging examinations of the respiratory system (X-ray and CT of the chest), LUS is characterized by high or comparable sensitivity and specificity in detecting pulmonary parenchyma pathology in various clinical situations.^{90,93,169,189,203–205} LUS is also used as a reference method in the diagnosis of the presence of free fluid in the pleural cavities.^{188,202,206,207}

Correctly performed, LUS allows for the detection of lung parenchyma pathology during the first contact with the patient, and in some cases it can replace other imaging methods.

Since LUS does not require the use of ionizing radiation, this test is safer for patients and may be an appropriate method to monitor the evolution of lung lesions and the course of treatment. In some cases, it also allows for the early diagnosis of complications as well as the stratification of the risk of a severe course of the disease, such as in COVID-19,²⁵ which strengthens the primary care physician/GP in making decisions about hospitalizing a patient or modifying therapeutic measures.^{139,196,200,208–213}

In conclusion, LUS can be successfully used for the assessment of basic pathological changes by non-radiologists in an outpatient care setting, even by personnel with limited experience in this examination.^{214,215}

Statement 13 (Clinical Statement)

LUS is feasible and useful in prehospital emergency medicine.

Guidelines—In any patient with acute dyspnea, the first diagnostic approach should include LUS.

Future Developments—Set a framework for the safe application of a portable US system in the out-of-hospital setting, while considering the specific condition to be diagnosed/monitored and the possibility of telemedicine.

Imaging is essential when dealing with critically ill patients, and LUS^{148,216} is a remarkably versatile²¹⁷ imaging technique which, thanks to portable US devices, can be effectively performed before reaching organized medical facilities or during transport.^{140,218}

In the pre-hospital emergency setting, LUS can provide immediate yes/no diagnostic answers, as well as in-depth diagnostic evaluations, enabling or facilitating patient decision-making and management, and optimizing the allocation of resources.^{219,220}

The most common applications of LUS on the field are thoracic injuries and respiratory failure.²²¹

Chest injuries represent the third most common cause of death in polytrauma patients,²²² and LUS allows a quick diagnosis of lung lesions, pneumothorax, and pleural effusion during emergency treatment and is therefore integrated into the focused assessment sonography for trauma (FAST) in the form of extended FAST (e-FAST) or abdominal chest FAST (CA-FAST).^{207,223,224}

LUS should also be included in the first diagnostic approach to any patient with acute dyspnea. It allows differential diagnosis between potentially life-threatening conditions such as pulmonary edema and bronchopneumonia, including moderate, severe, and critical lung injury associated with Sars Cov-2 related disease (COVID-19).^{24,25}

LUS may additionally assist interventional procedures to improve lung ventilation and or pulmonary edema resolution as part of resuscitation maneuvers and patient stabilization: positioning of catheters and tubes, pericardiocentesis, needle thoracostomy, and cricothyroidotomy.^{148,220}

Recently, pocket-sized wireless US probes have been made commercially available and clinically deployed, which allow receiving US clips directly on smartphones or tablets. These systems allow image transfer wireless or via e-mail, text messages, or cloud storage services allowing physicians to interpret images remotely via telemedicine. This type of hardware also promotes and facilitates the integration into clinical practice of automatic data analysis systems based on remotely stored processing algorithms that

can be made accessible via web-applications. Examples of such systems already emerged during the COVID-19 pandemic.^{18,20,24,35,57}

Indeed, some of these systems are highly ergonomic, waterproof, and resistant to cold conditions and, exploiting the screen technology and solid memory systems of modern smartphones and tablets, can be employed outdoor with bright lights even in wilderness environments.²²⁰

Specific guidelines for LUS in general and its possible telemedical applications must be implemented concerning: the medical personnel required formal training and qualification (Who), the adoption of specific protocols for focused assessment, and the specific profile of responsibility (How). It is also crucial to define those medical conditions which can be assessed with a focused approach (What), logistical and environmental conditions where a focused or telemedical approach may be advisable (Where), and the temporal frame (emergency-prehospital care) which makes acceptable the use diagnostic tools with a focused or telemedical approach.

Statement 14 (Clinical Statement)

LUS should be used by clinicians as a “point of care” examination in case of patient with dyspnea, chest pain, and any chest symptoms.

Future Developments—Harmonize specific protocols by disease/setting of use, such as lung congestion, pulmonary embolism, subpleural consolidation, ICU patient, and athlete after exertion by describing

- the image acquisition protocol (including the imaging settings);
- the typical LUS patterns w.r.t. the specific disease/setting.

Point-of-care US is performed by clinicians at bedside, followed by immediate visual interpretation and clinical integration of the imaging results.²²⁵

Extended Focused Assessment with Sonography for Trauma (E-FAST) scan protocol was the first point-of-care US examination performed in patients with recent chest trauma.²²⁶

Starting from the work of Lichtenstein et al,²²⁷ chest ultrasound examination (LUS) has become a widespread practice in the emergency room and intensive care, for the diagnosis of dyspnea.

In particular, since the second decade of the 2000s, many publications were produced on the use of US for the bedside diagnosis of acute pulmonary edema, ARDS, and pneumonia.^{56,228–232}

The main users were the emergency physicians and the intensivists, who benefited from the use of US scanners in different areas: emergency rooms, intensive care units, particular environmental rescue conditions.

The main object of interest was the differential diagnoses of dyspnea. LUS was utilized as an effective differential diagnostic tool between heart failure and pleuro-pulmonary involvement, as well as for questioning pulmonary embolism.^{232–234}

Moreover, the greater sensitivity of US compared with chest X-ray for detecting subpleural inflammatory consolidations, fostered the wide spreading of bedside diagnoses of pneumonia.¹⁰⁴

At the end of the first decade of the 2000s, several studies started indicating the possibility of improving the low specificity of the sonographic interstitial syndrome (SIS), which encompasses all vertical artifacts, that is, B-lines and white lung.

In particular, the possibility of differentiating between primary cardiogenic and pulmonary SIS was proposed to the differential diagnosis of cardiogenic edema, ARDS, and pulmonary fibrosis.⁵³

After 2010, pulmonologists and pediatricians began extensively exploring the point of care applications of thoracic US in their fields of interest.

Beyond the differential diagnosis between cardiogenic and primary pulmonary dyspnea, the interest of pulmonologists has also recently extended to the bedside evaluation of fibrosing interstitial lung diseases.^{39,154,235,236}

Furthermore, the recent COVID-19 pandemic has determined an exponential growth of research that confirmed the role of LUS as a useful point-of-care tool for diagnosis support, prognostic stratification and monitoring of COVID-19 pneumonias.^{24,25,101,237}

The pathologies that benefit most from LUS examination are dyspnea, thoracic trauma, COVID-19, pneumonia, pleural pathology (effusions and pneumothorax), and heart failure.^{56,228–230,238} The role of bedside US is relevant both in the diagnostic and in patient monitoring phases.

Clinicians should thus use LUS as a “point of care” examination in case of patient with dyspnea, chest pain and any chest symptom.

Point-of-care US examination of the chest remained for many years within the limits of a uniform assessment of the critically ill, regardless of the setting and pathology.

Instead, the most recent observations, both clinical and experimental, lead us to believe that both indications and specialist-settings, in which the point-of-care examination is performed, should be taken into consideration.^{39,154,233,238} This also applies to US scanners imaging settings, the selected probe and the number and distribution of scans to be acquired.^{39,57,101,239}

As an example, whether an algorithmic approach focused on the analysis of B-lines may be adequate for the interpretation of cardiogenic dyspnea in the emergency room or ICU,²³² the dyspnea of a chronically ill patient in pulmonary medicine settings requires a different evaluation of the US clips.¹¹⁴ Clinical integration and adaptation of the methodology to the specific setting is already ongoing.¹⁰²

In general, it is desirable that at least three aspects are detailed during the analysis of LUS data^{19,24–26,39}:

- Characteristics of the pleural line (see Statement 4);
- Characteristics, extension and distribution of the vertical artifacts (see Statement 5);
- Relationships with clinical data and integrated multiorgan sonography.

Finally, it is fundamental to indicate the adopted scanning protocol (clinically and technically motivated)^{43,57,102,119} for the use of focused thoracic US in contexts which are yet not fully explored, such as that of internal medicine, nephrology, infectious diseases, pediatrics, environments with limited resources, and hostile or extreme conditions (such as high altitudes, extreme sports, space flights, and high pressures).

As point-of-care ultrasonography continue to spread across medical specialties and care settings, future challenges are represented by a better understanding of when, how, and which point-of-care US examination must be used.

Statement 15 (Clinical Statement)

The technique of the examination depends on the clinical situation of the patient.

Guidelines—Perform LUS on the largest possible area of the chest that is available during LUS examination. Limitation of the area (field; region) examined may be justified by the patient's clinical condition, limited accessibility and other practical aspects, such as patient capability to cooperate, chest condition (scars, obesity).

Future Developments—Design studies to assess the diagnostic accuracy of LUS based on the available evidence for each disease/setting of application, using an appropriate gold standard.

Clinical conditions of the patient can influence LUS technique of examination.

Conventionally, LUS examinations should be performed covering the largest area of the chest available. As for auscultation with the stethoscope, the aim of LUS examination is to obtain information over all the explorable areas of the chest.¹⁵⁴

Whether the patient is able to keep the sitting position, it is advisable to start LUS examination on each hemithorax. After detecting the curtain sign at the costophrenic recess, begin from dorsal basal areas with ascending scans and place the probe in the intercostal spaces, tilting it to visualize the maximum extent of pleural line and subpleural space in the field of view. Then, move cranially along paravertebral areas avoiding the shadowing determined by shoulder blades. Intercostal scans should be performed in order to better examine peripheral lung parenchyma, focusing, and highlighting subpleural findings, and avoiding the shadowing determined by ribs.

The evaluation of dorsal basal regions can be considered important for many pleuro-pulmonary diseases (eg, free flowing pleural effusions, interstitial lung diseases, post embolic consolidations, etc^{240–242}), although without having complete specificity for the underlying disease. However, those scans should not be missed even in case of patients not able to keep the sitting position. Analogously, for COVID-19 pneumonia, dorsal basal scans should be always performed in order to avoid underestimation of the lung involvement.^{25,80,101,239} Lateral and anterior scans for each hemithorax can be performed with the same sequence of scans for both patient's supine and in sitting position.

The condition of the patient prior to examination should be always monitored in order to avoid

misleading features. This is particularly important for immobilized and lying patients, as atelectasis and increase of lung density can likely occur in peripheral lung areas.

Use thoracic anatomical lines and count intercostal spaces in order to indicate the position of any LUS finding. Detecting fissures during LUS examination can be useful to better indicate the position of that finding.²⁴³

It is preferable to use convex transducers (3–7 MHz) to examine the peripheral subpleural lung parenchyma, and to assess the presence and features of pleural effusions. Linear transducers (7–13 MHz) are also useful, and can be utilized to obtain a more detailed study of the pleuro-parenchymal interface and of the chest wall. Phased array transducers may be used to integrate LUS with data from echocardiography,¹⁵⁴ but due to the reduced spatial resolution and limited bandwidth are not recommended.

Both abdominal trans-hepatic and trans-splenic scans, using convex probe, can be useful to reach and evaluate diaphragmatic pleuro-parenchymal interface.²⁴⁴

Mediastinal pleura, visceral pleura inside fissures, and costal pleura are masked by shoulder blades and ribs, and are thus generally not accessible for US evaluation.^{245,246}

A standardized setting is recommended, especially to obtain information from artifactual patterns. LUS can be performed using low MI (see Statement 6), avoiding harmonic imaging and cosmetic filters, keeping the focal point on the pleural line, avoiding saturation phenomena of the pleural line and using the highest frame rate possible.^{24,39} Imaging modalities based on compounding should not be utilized, as they can generate deceiving artifactual patterns.²⁴⁷ Convex or linear probes should be used, according to the patient's body size.

Partial limitation of LUS examination is given by obesity, hypertrophic muscle mass, chest wall hematomas, chest deformity and abnormalities, scars at the region of interest and chest dressings.¹⁵⁴

Also, poor patient's cooperation due to coma, dementia, or altered mental state represent partial limitations.

Currently, the main limit for LUS evaluation is the presence of massive subcutaneous emphysema,

infiltration of air in the layers of the chest wall that hampers US penetration.²⁴⁶

Although the described conventional approach can be used widely, some pathologies or special conditions can require standardized protocols.

The recent pandemic by novel coronavirus represented a global emergency that needed a global unified approach.²⁴ To this end, a standardization for the international use of LUS for the management of COVID-19 patients was proposed.^{24,25,239}

Analogously, future studies could focus on defining the appropriate protocol of acquisition and analysis for specific pathologies in order to improve diagnostic accuracy and promote a standardized approach.

Statement 16 (Clinical Statement)

The functional assessment of the diaphragm may integrate the data of lung alteration to address or refine the differential diagnosis of respiratory failure in intensive care units (ICUs).

Guidelines—Perform functional assessment of the diaphragm to integrate the data of lung alteration, to address or refine the differential diagnosis of respiratory failure in ICUs, general wards and ambulatory settings. Functional assessment may for instance include

- thickening and thickening ratio
- diaphragmatic excursion
- speed of diaphragmatic contraction (slope of contraction)
- inspiratory time

Perform functional assessment of the diaphragm by carrying out the examination of the respiratory movements in the supine position, using a linear probe.

Diaphragm dysfunction should be promptly recognized in many clinical situations, especially in patients with respiratory failure in ICUs, to address the underlying causes since adapted ventilatory support may be necessary.^{248–250}

However, due to its non-specific presentation, diaphragm paralysis is often underdiagnosed. US allows a quick, generally available and dynamic method able to provide accurate information both on the anatomy and on the function of the muscle.^{251,252}

In many clinical conditions, US assessment of diaphragm is helpful in the identification and monitoring of diaphragm function, revealing diaphragm asymmetry, weakness, and paralysis.

In thoracic surgery, US allows diagnosis of post-operative diaphragm dysfunction potentially leading to failed extubation or prolonged mechanical ventilation.^{253,254}

Precisely, diaphragmatic excursions can predict extubation failure: when excursions exceed 25 mm or diaphragmatic thickening fraction DTF exceed 30–36% during spontaneous breathing trial, the likelihood of success increases.²⁵⁵

US may also be used as a guide for needle EMG to enhance accuracy and safety.

US examination of the diaphragm is carried out during spontaneous respiration and deep breathing.

The supine position offers higher diaphragm excursion, more reproducibility, and less variability, better correlation with diaphragm movement, exaggeration of any paradoxical movement, limitation of the compensatory action by the anterior abdominal wall.

US allows diaphragm thickness and mobility evaluation and the extension of the US diaphragm's zone of apposition (ZOA), namely the portion of the muscular fibres extending from their insertion on the ribs to the point where the diaphragm peels away from the rib cage.

US diaphragm thickness evaluation requires obtaining a US B-mode image with a linear probe positioned between the eighth and tenth ribs in the intercostal space on the anterior axillary line. Diaphragm thickness is estimated as the distance between the two bright, echogenic lines representing the pleural and peritoneal membranes where they result in parallel.²⁵⁶

Mobility evaluation involves an anterior subcostal view midclavicular line acquired through a convex transducer; in this scan line, M-mode allows the visualization of diaphragm motion as a time curve.²⁵⁷

ZOA assessment requires a large (8–12 cm) linear transducer vertically positioned against the right midaxillary line. The point where the diaphragm separates from the chest wall and the lung interposes is the cephalic margin of the zone of apposition, while the costal origin of the diaphragm is identified when the subject breathes in at total lung capacity and the length of the ZOA approaches zero.²⁴⁸

Statement 17 (Clinical Statement)

The most common sonographic features in case of pneumonia are: consolidation (with irregular marginal contour, air bronchogram, the air trapping sign), vertical artifacts (B-lines), and the presence of pleural effusion.

Specific Guidelines—In LUS assessment of pneumonia, describe the utilized protocol and ultrasonographic features, such as:

- consolidation (with irregular marginal contour, air bronchogram, air trapping sign),
- focal vertical/B-lines in the early or late presentation (see Statement 5),
- presence of pleural effusion,
- irregularity of the pleural line (see Statement 4).

Whenever possible, use Contrast Enhanced LUS to obtain further important information about peripheral consolidations.

Pneumonia is a large lung consolidation (segmental, lobar or more) caused by inflammatory/infectious events and characterized by symptoms, more frequently: dyspnoea, fever, cough, chest pain, and weakness.

The consolidated parenchyma, whether reaching visceral pleura where explorable by US scans, becomes accessible like any other parenchymal organ.¹⁵⁴ The possibility of carrying out a morphological examination allows for the description of some LUS features of lung consolidations.¹⁵⁵ In case of pneumonia, irregular shapes (at the deep and lateral edges) are reported (Shred sign).^{258,259} At the edges, inflamed lung parenchyma gradually increases aeration until normal spared lung. This pre-consolidated state of the lung, surrounding the consolidated core, determines the subversion of peripheral airspaces geometry, without reaching full consolidation. Heterogeneously shaped acoustic traps most likely develop in these transition areas where lung parenchyma moves from a consolidated to pre-consolidated state.⁴² This subverted parenchymal architecture is visualized by US scanners as a mix of artifacts, including differently shaped vertical artifacts arising from the edges of consolidations.^{39,42,154}

Analogously, pre-consolidated lung tissue surrounding the consolidation in the subpleural peripheral parenchyma, determines pleural irregularities,

vertical artifacts, and focal sonographic interstitial syndrome rising from the pleural line close to consolidations.^{154,233} These aspects can vary, depending on the degree of inflammation and phase of pathology, and are more represented during the acute phase while fading in late stages.

Air bronchogram²⁶⁰ is one of the most important signs to focus on. It represents air in peripheral airways, and reminds of the same term widely used with ionizing radiation based imaging. Contrarily to ionizing radiations, real time US assessment allows to check for air movement within the bronchogram during the act of breathing.

The presence of air movement (dynamic air bronchogram), in the context of a consolidation, has been reported as a useful sign to rule out obstructive atelectasis.^{261,262}

Instead, the absence of air movement, when air bronchogram is still detectable, can be associated with obstruction of airways. In this case, the horizontal and parallel distribution of bronchograms indicates also parenchymal collapse and volume reduction.^{154,260} On the contrary, tree-like shaped bronchograms is indicative of maintenance of lung volume without parenchymal collapse.

Fluid bronchogram occurs when air content of bronchi is substituted with fluids (eg, exudates, mucus, pus). It can be distinguishable from vessels in the context of a lung consolidation with the use of Doppler imaging.^{154,155,263} It has been reported more frequently in childhood pneumonia and in case of post-obstructive pneumonia.^{154,263–265}

Whenever possible, the use of contrast enhanced LUS can provide further information about peripheral consolidations (see Statement 11).

Pleural effusions can be associated with pneumonia. LUS assessment of pleural effusions characteristics can provide relevant clinical information, suggest interventional procedures, and guide them.^{103,266}

Statement 18 (Educational Statement)

It is strongly recommended to acquire adequate training in LUS before its implementation in the diagnostic process.

Guidelines—Adequate training should include courses focused on theoretical and practical aspects of LUS, hands-on sessions supervised by experts, as well as

case reviews of fundamental pleuro-pulmonary diseases. The minimal requirements for appropriate LUS training should include theoretical and practical basics (ie, as established in the EFSUMB recommendations). It is recommended to teach LUS as part of specialization programs in which LUS has clinical value. Continuous medical education on LUS is warranted to maintain proper quality.

Future Developments—It would be beneficial to find consensus on internationally recognized modalities to assess and certify the level of expertise in LUS reached by attendees during training. We encourage non physicians in performing LUS in different medical scenarios.

LUS has been viewed as an extension of the physical exam,^{267,268} as highlighted by the description of a stethoscope-like use,²⁶⁹ or the metaphor as being the stethoscope of the 21st century.²⁷⁰ As a diagnostic imaging method, quality criteria related to indication, image acquisition, interpretation, clinical integration, documentation, technological prerequisites as well as education, training, and quality assurance do apply. Findings are user-dependent.

Therefore, the definition of minimum education and training standards is needed before reliable diagnostic information can be retrieved, therapeutic consequences can be drawn and the findings be acknowledged as an adequate diagnostic imaging method by others.

Education and training in LUS can be delivered via classroom course formats,²⁷¹ or be part of specialization programs,^{272,273} with classic as well as new learning methods such as E-learning and blended learning for broader access of learners. Indeed, the latter have been proven feasible and effective.²⁷⁴ The response of educational institutions to pandemic-related restrictions in US education has boosted the application of virtual educational formats including real-time supervised practical training.^{275–278}

Scientific societies related to LUS have already issued minimum requirements.²⁷⁹ For education and training purposes, LUS can further be broken down into modalities with basic to advanced level qualification.²⁸⁰ Learning curves may be described as steep.²⁸¹ Furthermore, it has been shown that the application of LUS by different non-physician professions such as physiotherapists²⁸² or paramedics is feasible.^{283,284}

Educational science assessing LUS proficiency longitudinally from “zero” to independent clinical competence will be hard to acquire. On the other hand, there are already high and still increasing numbers of potential learners. As an example, in Germany LUS competence is required for more than 100,000 physicians regularly using “lung auscultation.” Therefore institutionalized nationwide training programs were introduced starting from 2008 (German Societies of Ultrasound in Medicine—DEGUM and Anaesthesiology and Critical Care Medicine—DGAI). Scientific evaluation accompanying learning assessment and certification thus is needed and should be encouraged to further set sufficient quality standards in the future.

Statement 19 (Educational Statement)

It is recommended to teach the basis of LUS as part of the students’ curriculum.

Guidelines—During medical education LUS should be taught as extensively as for other diagnostic modalities.

Future Developments—Nowadays, all medical students use a stethoscope during their medical education. It would be beneficial for students to embrace LUS and treat it as the next-generation stethoscope. This new percussion will open the window for better understanding of physiological and pathophysiological processes. Medical students should have access to US equipment during simulation courses, supervised hands-on sessions, as well as self-directed learning periods. LUS should become the semiotic “fifth pillar” of medical examination. Finally, medical students should treat LUS as the Point-of-Care modality for their future clinical practice.

LUS has been demonstrated to be a versatile, accurate, and easily learned bedside technique that demonstrates anatomy, physiology, pathophysiology, and the subsequent responses to therapy concerning cardiorespiratory injuries and diseases. Thus, the use of LUS is widely incorporated into clinical emergency care worldwide. Using LUS, innumerable diseases such as pneumothorax, pulmonary edema, pleural effusion, COVID-19 pneumonia, pulmonary contusion to name only a few can be assessed rapidly.^{223,232,285,286} Further, LUS is also shown to be

useful not only in POCUS examination to diagnose the cause of respiratory failure but also in understanding hemodynamics, guiding alveolar recruitment, and even assessing the decompression of a tension pneumothorax.^{103,287,288}

As LUS was dismissed by Traditional Medical Textbooks only a few years ago, most LUS practitioners have had to learn its use and refine their skills through combinations of on-the-job training and continuing educational activities. However, there is now the opportunity to incorporate LUS training into the basic education and training of all physicians learning the practice of medicine. As point of care US training becomes accepted as a core curriculum study in Medical School all physicians will gain competency. The World International Network Focused on Critical Ultrasound (WINFOCUS) has long supported this paradigm and holds regular scientific assemblies dedicated to this undertaking. Many Universities have already introduced this training into their undergraduate curriculum and have many years of experience with medical students learning US.^{289–291} Rationally, Educational Bodies are now recommending the incorporation of US training into the basic Medical School curriculum.²⁹⁰ Institutions with experience recommend integrating US training into multiple different educational opportunities and experiences. For instance, the University of South Carolina School of Medicine utilizes US images and demonstrations to complement courses without dedicated hands-on scanning sessions such as neuroanatomy, pathology, and introduction to clinical medicine problem-based learning (PBL) small groups,²⁸⁹ and the University of Calgary has incorporated basic US training into undergraduate anatomy and pathophysiology learning.²⁹²

Although the published experience is modest, LUS has been recognized as a critical and basic part of the Undergraduate Medical Curriculum. Celebi et al concluded that LUS training was a most basic and relevant skill to include in a standardized curriculum.²⁹⁰ The University of South Carolina Curriculum incorporates LUS in multiple scenarios at all train stages from basic didactic instruction to clinical incorporation in case-based scenarios.²⁸⁹ Lim et al designed a rotation specific LUS educational experience for medical students during their emergency department rotation.^{293,294} Similarly, Beaulieu

provided both didactic theory education for 2.5 hours and hands-on training for 2 hours to junior emergency medicine residents, and they reported a significant effect of training on the ability to perform LUS.²⁹⁵

Egalitarianism is urgently needed in medicine, both to off-load the overwhelming responsibilities on physicians but also to empower and respect allied health care professionals in a team endeavor. Thus, recent work noting that 10 directly supervised lung scans allowed a degree of LUS proficiency in Respiratory Therapists²⁹⁶ supports further initiatives to educate all point of care providers in LUS, not just physicians. Further, recent experience also confirms beneficial results from Emergency Medical Technician perform LUS.²⁸⁴ And finally, embracing the remarkable advances in personal informatics and global internet connectivity, it should be appreciated that remote experts may be able to guide all levels of first responders to perform emergency LUS when the situation requires,^{297–299} even in situations when a patient self-images.²⁸⁶

Statement 20 (Educational Statement)

Remote mentoring of US naive, but motivated and willing first responders has been shown to be a potentially accurate method of generating diagnostic quality US images that can then be interpreted by remote US experts.

Guidelines—Initial experience has demonstrated that remote mentoring of US naive self-isolating health subjects being remotely guided to image their own lungs, may be an accurate method of generating diagnostic quality US images that can then be interpreted by remote US experts.

Future Developments—It is essential that further remote mentoring experiences in realistic clinical situations continue, to be ready to face future pandemics.

US is a remarkable imaging technology³⁰⁰ and it allows for image interpretation remotely from the location of image generation, such that the responsible clinician can be physically removed from the patient.³⁰¹ With modern robust communications, imaging and guidance can occur in a real-time, but remote fashion with two-way communication.³⁰² Thus, inexperienced caregivers can be guided by

remote experts to obtain diagnostic quality images without the point of care caregiver being required to interpret or even understand the images obtained.³⁰³ This paradigm is designated as remote telementored ultrasonography (RTMUS) and has been the backbone of space medicine diagnostic imaging on board the International Space Station for many years.^{304–306} RTMUS has involved both inexperienced care providers imaging other team members, as well as even being remotely guided to image themselves in a paradigm that can be considered Remote Telementored Self-performed ultrasound (RTMSPUS).

Much ongoing work has been conducted on earth demonstrating the feasibility and accuracy of RTMUS in terrestrial settings. A fixed internet connection between an urban trauma center and a rural mountain referring center demonstrated real time patient benefits of early diagnosis of hemoperitoneum, remote pneumothorax diagnosis, and even expedited emergency room bypass with direct to operating room resuscitation.³⁰⁷ Numerous other studies have both confirmed the accuracy and practicality of the paradigm while examining logistical factors in simulation.^{297,298,308,309}

Through the work on board the International Space Station,³⁰⁶ examining self-performed telementored ultrasonography (SPTMUS),³⁰⁶ it has long been known that accurate US images such as those of the lungs can be self-obtained by US naive users.^{298,299,308,310,311} There has been much less translational effort however to develop this paradigm compared with RTMUS performed upon others. Just as COVID-19 however, has changed so much in the modern universe, it also provides great impetus to consider the paradigm of an intelligent, motivated, but untrained user to obtained remotely guided images of their own lung health. LUS is a potentially home-based technology that might be used for at-risk patients to self-monitor their lungs of for early signs of COVID-19 pneumonia.^{24,25,101,153} COVID-19 pneumonia lung findings are typically present in the lung periphery,^{312–314} allowing LUS to diagnose and manage all phases of care in COVID-19. The TeleMentored Ultrasound Supported Medical Interventions (TMUSMIS) group recently confirmed the feasibility of RTMSPUS LUS working with inexperienced volunteers asked to perform their own guided lung surveillance examinations to rule out features of

COVID-19 pneumonia.²⁸⁶ It was shown that non-medical laypeople could utilize an ultraportable smart-phone powered US probe and receive just-in-time guidance from a remote expert. Participants were able to image their anterior, lateral, and bases of their backs with a 99.8% adequacy rate as assessed by blinded LUS reviewers although only two-thirds could fully image their backs. More importantly, the COVID hot spots of the bases of the lungs could be imaged in 96% of cases.²⁸⁶ In this paradigm, all interpretation of the LUS findings are the responsibility of the remote mentor. The implications of this paradigm are the potential to guide isolated or unreachable patients to self-image innumerable medical or traumatic conditions if they have an US capability and communications.

Unfortunately, COVID-19 is predicted to be just one of many future zoonotic-based pandemics that will afflict humans in the future.³¹⁵ Experiences with overwhelmed health systems, and critical shortages of everything, especially human resources, logically prompted recommendations to employ telemedical capabilities to provide advanced outreach capabilities, for the “entire population not only for hospitals.”³¹⁶ Thus, the RTMSPUS paradigm should be further explored as a means of not just improving individual patient care, but to protect care providers and to potentiate their outreach and clinical coverage of the general public.

Discussion and Conclusion

After 10 years since the first consensus was published in 2012, the need was felt for an updated international consensus on the use of LUS.

Differently from the document of 2012, we have introduced a significant element of novelty by including a broader range of expertise in the formulation and evaluation of the statements, guidelines and future developments. This allowed bringing together in one document the views of clinicians, engineers and physicists. For the first time, important aspects concerning technical and safety aspects, previously overlooked, have emerged from this synthesis. As a result, 20 statements have been produced, characterized as technical (5), safety (1), clinical (11), and educational (3) statements.

In this document, we also promote the need for standardization of the imaging protocols and analysis procedures, which may be tailored to specific pathologies. This type of approach will foster reproducibility, support the development, implementation, and validation of automated systems, and permit the comparability of results across different studies.

We view this document as a starting point for further international collaborations and foresee the need to update this international consensus with a time frame of 5 years. Indeed, while statements and guidelines can be seen as a description of the state of the art in LUS, future developments should be considered as a forward-looking perspective on the most clinically relevant and scientifically challenging questions. We invite from now clinicians, engineers and physicists to join in the effort of expanding and strengthening the LUS community. Improving the reproducibility, accuracy, reliability, and awareness of LUS will in fact produce shared benefits for research, the health care sector, and patients.

Acknowledgment

Open Access Funding provided by Università degli Studi di Trento within the CRUI-CARE Agreement.

References

- Okoli C, Pawlowski SD. The Delphi method as a research tool: an example, design considerations and applications. *Inf Manag* 2004; 42:15–29.
- Akins RB, Tolson H, Cole BR. Stability of response characteristics of a Delphi panel: application of bootstrap data expansion. *BMC Med Res Methodol* 2005; 5:37.
- Santaguida P, Dolovich L, Oliver D, et al. Protocol for a Delphi consensus exercise to identify a core set of criteria for selecting health related outcome measures (HROM) to be used in primary health care. *BMC Fam Pract* 2018; 19:152.
- Boers M, Kirwan J, Tugwell P, Beaton D, Bingham CO, Conaghan PG. The OMERACT handbook; 2015. https://www.omeract.org/omeract_publications.php 2017. Accessed August 7, 2019.
- Lynn MR. Determination and quantification of content validity. *Nurs Res* 1986; 35:382–385.
- Harris PA, Taylor R, Thielke R, Payne J, Gonzalez N, Conde JG. Research electronic data capture (REDCap) – a metadata-driven methodology and workflow process for providing translational research informatics support. *J Biomed Inform* 2009; 42:377–381.
- Harris PA, Taylor R, Minor BL, et al. REDCap consortium, the REDCap consortium: building an international community of software partners. *J Biomed Inform* 2019; 9.
- Menchón-Lara RM, Sancho-Gómez JL. Fully automatic segmentation of ultrasound common carotid artery images based on machine learning. *Neurocomputing* 2015; 151:161–167.
- Shan J, Alam SK, Garra B, Zhang Y, Ahmed T. Computer-aided diagnosis for breast ultrasound using computerized BI-RADS features and machine learning methods. *Ultrasound Med Biol* 2016; 42:980–988.
- Burlina P, Billings T, Joshi N, Albayda J. Automated diagnosis of myositis from muscle ultrasound: exploring the use of machine learning and deep learning methods. *PLoS One* 2017; 12: e0184059.
- Arntfield R, Wu D, Tschirhart J, et al. Automation of lung ultrasound interpretation via deep learning for the classification of normal versus abnormal lung parenchyma: a multicenter study. *Diagnostics* 2021; 11:2049.
- Zheng X, Kulhare S, Mehanian C, Chen Z, Wilson B. Feature detection and pneumonia diagnosis based on clinical lung ultrasound imagery using deep learning. *J Acoust Soc Am* 2018; 144:1668.
- Tsai CH, van der Burgt J, Vukovic D, et al. Automatic deep learning-based pleural effusion classification in lung ultrasound images for respiratory pathology diagnosis. *Phys Med* 2021; 83: 38c45.
- Arntfield R, VanBerlo B, Alaifan T, et al. Development of a convolutional neural network to differentiate among the etiology of similar appearing pathological B lines on lung ultrasound: a deep learning study. *BMJ Open* 2021; 11:e045120.
- Frank O, Schipper N, Vaturi M, et al. Integrating domain knowledge into deep networks for lung ultrasound with applications to COVID-19, [published online ahead of print October 2021]. *IEEE Trans Med Imaging* 2022; 41:571–581.
- Krishnaswamy D, Ebadi SE, Bolouri SES, et al. A novel machine learning-based video classification approach to detect pneumonia in COVID-19 patients using lung ultrasound. *IJNCD* 2021; 6:69.
- Diaz-Escobar J, Ordóñez-Guillén NE, Villarreal-Reyes S, et al. Deep-learning based detection of COVID-19 using lung ultrasound imagery. *PLoS One* 2021; 16:e0255886.
- Roy S, Menapace W, Oei S, et al. Deep learning for classification and localization of COVID-19 markers in point-of-care lung ultrasound. *IEEE Trans Med Imaging* 2020; 39:2676–2687.
- Carrer L, Donini E, Marinelli D, et al. Automatic pleural line extraction and COVID-19 scoring from lung ultrasound data. *IEEE Trans Ultrason Ferroelectr Freq Control* 2020; 67:2207–2217.
- Mento F, Perrone T, Fiengo A, et al. Deep learning applied to lung ultrasound videos for scoring COVID-19 patients: a multi-center study. *J Acoust Soc Am* 2021; 149:3626.

21. Roshankhah R, Karbalaiesadegh Y, Greer H, et al. Investigating training-test data splitting strategies for automated segmentation and scoring of COVID-19 lung ultrasound images. *J Acoust Soc Am* 2021; 150:4118.
22. Fatima N, Mento F, Zanforlin A, et al. Human-to- Ai interrater agreement for lung ultrasound scoring in COVID-19 Patients. *J Ultrasound Med*. Published online July 07, 2022. <https://doi.org/10.1002/jum.16052>
23. Mento F, Perronev T, Fiengo A, et al. Multicenter study Assessing Artificial Intelligence Capability in Scoring Lung Ultrasound Videos of COVID-19 Patients. Proceeding of the IEEE International Ultrasonics Symposium 2012, Virtual Meeting.
24. Soldati G, Smargiassi A, Inchingolo R, et al. Proposal for international standardization of the use of lung ultrasound for patients with COVID-19: a simple, quantitative, reproducible method. *cc* 2020; 39:1413–1419.
25. Perrone T, Soldati G, Padovini L, et al. A new lung ultrasound protocol able to predict worsening in patients affected by severe acute respiratory syndrome coronavirus 2 pneumonia. *J Ultrasound Med* 2021; 40:1627–1635.
26. Soldati G, Demi M, Inchingolo R, Smargiassi A, Demi L. On the physical basis of pulmonary sonographic interstitial syndrome. *J Ultrasound Med* 2016; 35:2075–2086.
27. Moore CL, Copel JA. Point-of-care ultrasonography. *N Engl J Med* 2011; 364:749–757.
28. Soldati G, Smargiassi A, Inchingolo R, et al. Is there a role for lung ultrasound during the COVID-19 pandemic? *J Ultrasound Med* 2020; 39:1459–1462. <https://doi.org/10.1002/jum.15284>.
29. Seibel A, Heinz W, Greim CA, Weber S. Lung ultrasound in COVID-19. *Anaesthesist* 2021; 70:146–154.
30. Jackson K, Butler R, Aujayeb A. Lung ultrasound in the COVID-19 pandemic. *Postgrad Med J* 2021; 97:34–39. <https://doi.org/10.1136/postgradmedj-2020-138137>.
31. Allinovi M, Parise A, Giacalone M, et al. Lung ultrasound may support diagnosis and monitoring of COVID-19 pneumonia. *Ultrasound Med Biol* 2020; 46:2908–2917.
32. Smith MJ, Hayward SA, Innes SM, Miller ASC. Point-of-care lung ultrasound in patients with COVID-19 - a narrative review. *Anaesthesia* 2020; 75:1096–1104.
33. Moore S, Gardiner E. Point of care and intensive care lung ultrasound: a reference guide for practitioners during COVID-19. *Radiography (Lond)* 2020; 26:e297–e302.
34. Hussain A, Via G, Melniker L, et al. Multi-organ point-of-care ultrasound for COVID-19 (PoCUS4COVID): international expert consensus. *Crit Care* 2020; 24:702.
35. Khan U, Mento F, Nicolussi LG, et al. Deep learning-based classification of reduced lung ultrasound data from COVID-19 patients. *IEEE Trans Ultrason Ferroelectr Freq Control* 2022; 9: 1661–1669.
36. Soldati G, Inchingolo R, Smargiassi A, et al. Ex vivo lung sonography: morphologic-ultrasound relationship. *Ultrasound Med Biol* 2012; 38:1169–1179.
37. Soldati G, Smargiassi A, Inchingolo R, et al. Lung ultrasonography and vertical artifacts: the shape of air. *Respiration* 2015; 90: 86. <https://doi.org/10.1159/000430483>.
38. Soldati G, Smargiassi A, Inchingolo R, et al. Lung ultrasonography may provide an indirect estimation of lung porosity and air-space geometry. *Respiration* 2014; 88:458–468. <https://doi.org/10.1159/000368086>.
39. Soldati G, Demi M, Smargiassi A, Inchingolo R, Demi L. The role of ultrasound lung artifacts in the diagnosis of respiratory diseases. *Expert Rev Respir Med* 2019; 13:163–172.
40. Mohanty K, Blackwell J, Egan T, Muller M. Characterization of the lung parenchyma using ultrasound multiple scattering. *Ultrasound Med Biol* 2017; 43:993–1003.
41. Demi M, Soldati G, Demi L. On the artefactual information of ultrasound lung images. *POMA* 2018; 144:1669.
42. Soldati S, Smargiassi A, Demi L, Inchingolo R. Artifactual lung ultrasonography: it is a matter of traps, order, and disorder. *Appl Sci* 2020; 10:1570–1583.
43. Demi M, Prediletto R, Soldati G, Demi L. Physical mechanisms providing clinical information from ultrasound lung images: hypotheses and early confirmations. *IEEE Trans Ultrason Ferroelectr Freq Control* 2020; 67:612–623.
44. Demi L, van Hoeve W, van Sloun RJG, Soldati G, Demi M. Determination of a potential quantitative measure of the state of the lung using lung ultrasound spectroscopy. *Sci Rep* 2017; 7:12746.
45. Demi L, van Hoeve W, van Sloun RJ, Demi M, Soldati G. The native frequency of B-lines artifacts may provide a quantitative measure of the state of the lung. *J Acoust Soc Am* 2017; 141: 3955. <https://doi.org/10.1121/1.4988990>.
46. Peschiera E, Mento F, Demi L. Numerical study on lung ultrasound B-line formation as a function of imaging frequency and alveolar geometries. *J Acoust Soc Am* 2021; 149:2304.
47. Mento F, Demi L. On the influence of imaging parameters on lung ultrasound B-line artifacts, in vitro study. *J Acoust Soc Am* 2020; 148:975. <https://doi.org/10.1121/10.0001797>.
48. Mento F, Demi L. Dependence of lung ultrasound vertical artifacts on frequency, bandwidth, focus and angle of incidence: an in vitro study. *J Acoust Soc Am* 2021; 150:4075.
49. Demi L, Demi M, Prediletto R, Soldati G. Real-time multi-frequency ultrasound imaging for quantitative lung ultrasound – first clinical results. *J Acoust Soc Am* 2020; 148:998.
50. Miller DL, Dou C, Raghavendran K. Pulmonary capillary hemorrhage induced by fixed-beam pulsed ultrasound. *Ultrasound Med Biol* 2015; 41:2212–2219.
51. Jambrik Z, Monti Z, Coppola V, et al. Usefulness of ultrasound lung comets as non-radiologic sign of extravascular lung water. *Am J Cardiol* 2004; 93:1265–1270.

52. Reissig A, Kroegel C. Transthoracic sonography of diffuse parenchymal lung disease. *J Ultrasound Med* 2003; 22:173–180.
53. Copetti R, Soldati G, Copetti P. Chest sonography: a useful tool to differentiate acute cardiogenic pulmonary edema from acute respiratory distress syndrome. *Cardiovasc Ultrasound* 2008; 6:16.
54. Volpicelli G, Frascisco MF. Sonographic detection of radio-occult interstitial lung involvement in measles pneumonitis. *Am J Emerg Med* 2009; 27:128.e1–128.e3.
55. Soldati G, Copetti R, Sher S. Sonographic interstitial syndrome: the sound of lung water. *J Ultrasound Med* 2009; 28:163–174.
56. Volpicelli G, Elbarbary M, Blaivas M, et al. International liaison committee on lung ultrasound (ILC-LUS) for the international consensus conference on lung ultrasound (ICC-LUS), international evidence-based recommendations for point-of-care lung ultrasound. *Intensive Care Med* 2012; 38:577–591.
57. Demi L. Lung ultrasound: the future ahead and the lessons learned from COVID-19. *J Acoust Soc Am* 2020; 148:2146.
58. Demi L, Egan T, Muller M. Lung ultrasound imaging, a technical review. *Appl Sci* 2020; 10:462.
59. Ostras O, Soulioti DE, Pinton G. Diagnostic ultrasound imaging of the lung, a simulation approach based on propagation and reverberation in the human body. *J Acoust Soc Am* 2021; 150:3904–3913.
60. Kameda T, Kamiyama N, Kobayashi H, Kanayama Y, Taniguchi N. Ultrasonic B-line-like artifacts generated with simple experimental models provide clues to solve key issues in B-lines. *Ultrasound Med Biol* 2019; 45:1617–1626.
61. Kameda T, Kamiyama N, Taniguchi N. Simple experimental models for elucidating the mechanism underlying vertical artifacts in lung ultrasound: tools for revisiting B-lines. *Ultrasound Med Biol* 2021; 47:3543–3555.
62. Matthias I, Panebianco NL, Maltenfort MG, Dean AJ, Baston C. Effect of machine settings on ultrasound assessment of B-lines. *J Ultrasound Med* 2020; 40:2039–2046.
63. Mento F, Soldati G, Prediletto R, Demi M, Demi L. Quantitative lung ultrasound spectroscopy applied to the diagnosis of pulmonary fibrosis: first clinical study. *IEEE Trans Ultrason Ferroelectr Freq Control* 2020; 67:2265–2273.
64. Soldati G, Demi M. The use of lung ultrasound images for the differential diagnosis of pulmonary and cardiac interstitial pathology. *J Ultrasound* 2017; 20:91–96.
65. Marchetti G, Arondi S, Baglivo F, et al. New insights in the use of pleural ultrasonography for diagnosis and treatment of pleural disease. *Clin Respir J* 2018; 12:1993–2005.
66. Alonso-Ojembarrena A, Lechuga-Sancho AM, Ruiz-González E, González-Haba-Martínez B, Lubián-López SP. Pleural line thickness reference values for preterm and term newborns. *Pediatr Pulmonol* 2020; 55:2296–2301. <https://doi.org/10.1002/ppul.24920>.
67. Kumar I, Siddiqui Z, Verma A, Chokhani A, Srivastava GN, Shukla RC. Performance of semi-quantitative lung ultrasound in the assessment of disease severity in interstitial lung disease. *Ann Thorac Med* 2021; 16:110–117.
68. Soldati G, Giannasi G, Smargiassi A, Inchingolo R, Demi L. Contrast-enhanced ultrasound in patients with COVID-19: pneumonia, acute respiratory distress syndrome, or something else? *J Ultrasound Med* 2020; 39:2483–2489.
69. Sultan LR, Chen YT, Cary TW, Ashi K, Sehgal CM. Quantitative pleural line characterization outperforms traditional lung texture ultrasound features in detection of COVID-19. *J Am Coll Emerg Physicians Open* 2021; 2:e12418.
70. Jiangang C, Chao H, Jintao Y, et al. Quantitative analysis and automated lung ultrasound scoring for evaluating COVID-19 pneumonia with neural networks. *IEEE Trans Ultrason Ferroelectr Freq Control* 2020; 68:2507–2515.
71. Wufeng X, Chunyan C, Jie L, et al. Modality alignment contrastive learning for severity assessment of COVID-19 from lung ultrasound and clinical information. *Med Image Anal* 2021; 69:101975. <https://doi.org/10.1016/j.media.2021.101975>.
72. Wolfram F, Braun C, Gutsche H, Lesser TG. In vivo assessment of lung ultrasound features mimicking viral pneumonia using a large animal model. *IEEE Trans Ultrason Ferroelectr Freq Control* 2020; 67:2258–2264. <https://doi.org/10.1109/TUFFC.2020.3010299>.
73. Sakai F, Sone S, Kiyono K, et al. High resolution ultrasound of the chest wall. *Rofo* 1990; 153:390–394.
74. Weibel ER. How to make an alveolus. *Eur Respir J* 2008; 31:483–485.
75. Connie CWH, Dallas MH, Ewald RW. Lung structure and the intrinsic challenges of gas exchange. *Compr Physiol* 2016; 6:827–895.
76. Scarpelli EM. Physiology of the alveolar surface network: a new anatomy and its physiological significance. *Anat Rec* 1998; 251:491–527.
77. Demi L, Demi M, Smargiassi A, Inchingolo R, Fata F, Soldati G. Ultrasonography in lung pathologies: new perspectives. *Multidiscip Respir Med* 2014; 9:27.
78. Weibel ER. A retrospective of lung morphometry: from 1963 to present. *Am J Physiol Lung Cell Mol Physiol* 2013; 305:L405–L408.
79. Mathis G. Pneumonia: does ultrasound replace chest X-ray? *Praxis (Bern 1994)* 2018; 107:1283–1287.
80. Gutsche H, Lesser T, Wolfram F, et al. Significance of lung ultrasound in patients with suspected COVID-19 infection at hospital admission. *Diagnostics* 2021; 11:921.
81. Church CC, Carstensen EL, Nyborg WL, Carson PL, Frizzell LA, Bailey MR. The risk of exposure to diagnostic ultrasound in postnatal subjects: nonthermal mechanisms. *J Ultrasound Med* 2008; 27:565–592.
82. Miller DL. Mechanisms for induction of pulmonary capillary hemorrhage by diagnostic ultrasound: review and consideration of acoustical radiation surface pressure. *Ultrasound Med Biol* 2016; 42:2743–2757.

83. Miller DL, Suresh MV, Dou C, Yu B, Raghavendran K. Characterization of ultrasound-induced pulmonary capillary hemorrhage in rats. *Microvasc Res* 2014; 93:42–45.
84. Miller DL, Dong Z, Dou C, Patterson B, Raghavendran K. Pulmonary capillary hemorrhage induced by super sonic shear wave elastography in rats. *Ultrasound Med Biol* 2019; 45:2993–3004.
85. Miller DL, Dong Z, Dou C, Raghavendran K. Influence of scan duration on pulmonary capillary hemorrhage induced by diagnostic ultrasound. *Ultrasound Med Biol* 2016; 42:1942–1950.
86. Medical Ultrasound Society British (BMUS). Physics and Safety Statements. BMUS [Online]; 2009. <https://www.bmus.org/policies-statements-guidelines/safety-statements/>
87. American Institute of Ultrasound in Medicine (AIUM). Official Statements [Online]; 2015. https://www.aium.org/official-statements/6?__sw_csrfToken=3e7d4f17
88. Patterson B, Miller DL. Experimental measurements of ultrasound attenuation in human chest wall and assessment of the mechanical index for lung ultrasound. *Ultrasound Med Biol* 2020; 46:1442–1454.
89. Abramowicz JS. *Medical Ultrasound Safety*. 4th ed. AIUM; 2020.
90. Ye X, Xiao H, Chen B, Zhang S. Accuracy of lung ultrasonography versus chest radiography for the diagnosis of adult community-acquired pneumonia: review of the literature and meta-analysis. *PLoS One* 2015; 10:e0130066.
91. Song G, Bae SC, Lee YH. Diagnostic accuracy of lung ultrasound for interstitial lung disease in patients with connective tissue diseases: a meta-analysis. *Clin Exp Rheumatol* 2016; 34: 11–16.
92. Squizzato A, Rancan E, Dentali F, et al. Diagnostic accuracy of lung ultrasound for pulmonary embolism: a systematic review and meta-analysis. *J Thromb Haemost* 2013; 11:1269–1278.
93. Xia Y, Ying Y, Wang S, Li W, Shen H. Effectiveness of lung ultrasonography for diagnosis of pneumonia in adults: a systematic review and meta-analysis. *J Thorac Dis* 2016; 8:2822–2831.
94. Alrajab S, Youssef AM, Akkus NI, Caldito G. Pleural ultrasonography versus chest radiography for the diagnosis of pneumothorax: review of the literature and meta-analysis. *Crit Care* 2013; 17: R208.
95. Al Deeb M, Barbic S, Featherstone R, Dankoff J, Barbic D. Point-of-care ultrasonography for the diagnosis of acute cardiogenic pulmonary edema in patients presenting with acute dyspnea: a systematic review and meta-analysis. *Acad Emerg Med* 2014; 21: 843–852.
96. Alrajhi K, Woo MY, Vaillancourt C. Test characteristics of ultrasonography for the detection of pneumothorax: a systematic review and meta-analysis. *Chest* 2012; 141:703–708.
97. Najgrodzka P, Buda N, Zamojska A, Marciniwicz E, Lewandowicz-Uszyńska A. Lung ultrasonography in the diagnosis of pneumonia in children—a metaanalysis and a review of pediatric lung imaging. *Ultrasound Q* 2019; 35:157–163.
98. Buda N, Kosiak W, Wełnicki M, et al. Recommendations for lung ultrasound in internal medicine. *Diagnostics (Basel)* 2020; 10:597.
99. Jaworska J, Komorowska-Piotrowska A, Pomiećko A, et al. Consensus on the application of lung ultrasound in pneumonia and bronchiolitis in children. *Diagnostics (Basel)* 2020; 10:935.
100. Liu J, Guo G, Kurepa D, et al. Specification and guideline for technical aspects and scanning parameter settings of neonatal lung ultrasound examination. *J Matern Fetal Neonatal Med* 2021; 1–14.
101. Demi L, Mento F, Di Sabatino A, et al. Lung ultrasound in COVID-19 and post-COVID-19 patients, an evidence-based approach. *J Ultrasound Med* 2022; 41:2203–2215.
102. Soldati G, Smargiassi A, Mariani AA, Inchingolo R. Novel aspects in diagnostic approach to respiratory patients: is it the time for a new semiotics? *Multidiscip Respir Med* 2017; 12:15.
103. Havelock T, Teoh R, Laws D, Gleeson F. BTS pleural disease guideline group. Pleural procedures and thoracic ultrasound: British Thoracic Society pleural disease guideline 2010. *Thorax* 2010; 65:ii61–ii76. <https://doi.org/10.1136/thx.2010.137026>.
104. Chavez MA, Shams N, Ellington LE, et al. Lung ultrasound for the diagnosis of pneumonia in adults: a systematic review and meta-analysis. *Respir Res* 2014; 15:50.
105. Orso D, Guglielmo N, Copetti R. Lung ultrasound in diagnosing pneumonia in the emergency department: a systematic review and meta-analysis. *Eur J Emerg Med* 2018; 25:312–321.
106. Pereda MA, Chavez MA, Hooper-Miele CC, et al. Lung ultrasound for the diagnosis of pneumonia in children: a meta-analysis. *Pediatrics* 2015; 135:714–722.
107. Orso D, Ban A, Guglielmo N. Lung ultrasound in diagnosing pneumonia in childhood: a systematic review and meta-analysis. *J Ultrasound* 2018; 21:183–195.
108. Ron E, Alattar Z, Hoebee S, Kang P, Van Sonnenberg E. Current trends in the use of ultrasound over chest X-ray to identify pneumothoraces in ICU, trauma, and ARDS patients. *J Intensive Care Med* 2022; 37:5–11.
109. Ding W, Shen Y, Yang J, He X, Zhang M. Diagnosis of pneumothorax by radiography and ultrasonography: a meta-analysis. *Chest* 2011; 140:859–866.
110. Dahmarde H, Parooie F, Salarzaei M. Accuracy of ultrasound in diagnosis of pneumothorax: a comparison between neonates and adults—a systematic review and meta-analysis. *Can Respir J* 2019; 2019:5271982.
111. Fei Q, Lin Y, Yuan TM. Lung ultrasound, a better choice for neonatal pneumothorax: a systematic review and meta-analysis. *Ultrasound Med Biol* 2021; 47:359–369.
112. Wang Y, Shen Z, Lu X, Zhen Y, Li H. Sensitivity and specificity of ultrasound for the diagnosis of acute pulmonary edema: a systematic review and meta-analysis. *Med Ultrason* 2018; 1: 32–36.

113. Maw AM, Hassanin A, Ho PM, et al. Diagnostic accuracy of point-of-care lung ultrasonography and chest radiography in adults with symptoms suggestive of acute decompensated heart failure: a systematic review and meta-analysis. *JAMA Netw Open* 2019; 2:e190703.
114. Soldati G, Demi M, Demi L. Ultrasound patterns of pulmonary edema. *Ann Transl Med* 2019; 7:S16.
115. Yamamoto K, Kinugasa Y, Sugihara S, Mukai-Yatagai N, Kato M. Ultrasonographic assessment of organs other than the heart in patients with heart failure. *J Med Ultrason* 2019; 46:389–397. <https://doi.org/10.1007/s10396-019-00953-3>.
116. Elsayed YN, Hinton M, Graham R, Dakshinamurti S. Lung ultrasound predicts histological lung injury in a neonatal model of acute respiratory distress syndrome. *Pediatr Pulmonol* 2020; 55: 2913–2923.
117. Wu J, Wang Y, Zhao A, Wang Z. Lung ultrasound for the diagnosis of neonatal respiratory distress syndrome: a meta-analysis. *Ultrasound Q* 2020; 36:102–110.
118. Ma H, Yan W, Liu J. Diagnostic value of lung ultrasound for neonatal respiratory distress syndrome: a meta-analysis and systematic review. *Med Ultrason* 2020; 22:325–333.
119. Zambon M, Greco M, Bocchino S, Cabrini L, Beccaria PF, Zangrillo A. Assessment of diaphragmatic dysfunction in the critically ill patient with ultrasound: a systematic review. *Intensive Care Med* 2017; 43:29–38.
120. Li C, Li X, Han H, Cui H, Wang G, Wang Z. Diaphragmatic ultrasonography for predicting ventilator weaning: a meta-analysis. *Medicine (Baltimore)* 2018; 97:e10968.
121. Le Neindre A, Philippart F, Luperto M, et al. Diagnostic accuracy of diaphragm ultrasound to predict weaning outcome: a systematic review and meta-analysis. *Int J Nurs Stud* 2021; 117:103890.
122. Santos-Silva J, Lichtenstein D, Tuinman PR, Elbers PWG. The lung point, still a sign specific to pneumothorax. *Intensive Care Med* 2019; 45:1327–1328.
123. Lichtenstein DA, Mezière G, Lascols N, et al. Ultrasound diagnosis of occult pneumothorax. *Crit Care Med* 2005; 33:1231–1238.
124. Lichtenstein D, Mezière G, Biderman P, Gepner A. The “lung point”: an ultrasound sign specific to pneumothorax. *Intensive Care Med* 2000; 26:1434–1440.
125. Oelze ML, Miller RJ, Blue JP, et al. Estimation of the acoustic impedance of lung versus level of inflation for different species and ages of animals. *J Acoust Soc Am* 2008; 124:2340–2352.
126. Szabo TL. *Diagnostic ultrasound imaging*. Amsterdam: Elsevier Academic Press; 2004.
127. Dubón-Peralta EE, Lorenzo-Villalba N, García-Klepzig JL, Andrés E, Méndez-Bailon M. Prognostic value of B lines detected with lung ultrasound in acute heart failure. A systematic review. *J Clin Ultrasound* 2021; 50:273–283.
128. McGiverty K, Atkinson P, Lewis D, et al. Emergency department ultrasound for the detection of B-lines in the early diagnosis of acute decompensated heart failure: a systematic review and meta-analysis. *CJEM* 2018; 20:343–352.
129. Soldati G, Giunta V, Sher S, et al. Synthetic comets: a new look at lung sonography. *Ultrasound Med Biol* 2011; 37:1762–1770.
130. Buessler A, Chouihed T, Duarte K, et al. Accuracy of several lung ultrasound methods for the diagnosis of acute heart failure in the ED: a multicenter prospective study. *Chest* 2020; 157: 99–110.
131. Koh Y, Chua MT, Ho WH, Lee C, Chan GWH, Sen KW. Assessment of dyspneic patients in the emergency department using point-of-care lung and cardiac ultrasonography—a prospective observational study. *J Thorac Dis* 2018; 10:6221–6229.
132. Garibyan VN, Amundson SA, Shaw DJ, Phan JN, Showalter BK, Kimura BJ. Lung ultrasound findings detected during inpatient echocardiography are common and associated with short- and long-term mortality. *J Ultrasound Med* 2018; 37:1641–1648.
133. Dwyer KH, Merz AA, Lewis EF, et al. Pulmonary congestion by lung ultrasound in ambulatory patients with heart failure with reduced or preserved ejection fraction and hypertension. *J Card Fail* 2018; 24:219–226.
134. Wooten WM, Shaffer LET, Hamilton LA. Bedside ultrasound versus chest radiography for detection of pulmonary edema: a prospective cohort study. *J Ultrasound Med* 2019; 38:967–973.
135. Scali MC, Zagatina A, Simova I, et al. B-lines with lung ultrasound: the optimal scan technique at rest and during stress. *Ultrasound Med Biol* 2017; 43:2558–2566.
136. Li H, Li YD, Zhu WW, et al. A simplified ultrasound comet tail grading scoring to assess pulmonary congestion in patients with heart failure. *Biomed Res Int* 2018; 2018:8474839.
137. Picano E, Ciampi Q, Citro R, et al. Stress echo 2020: the international stress echo study in ischemic and non-ischemic heart disease. *Cardiovasc Ultrasound* 2017; 15:3.
138. Pivetta E, Goffi A, Nazerian P, et al. Lung ultrasound integrated with clinical assessment for the diagnosis of acute decompensated heart failure in the emergency department: a randomized controlled trial. *Eur J Heart Fail* 2019; 21:754–766.
139. Pellicori P, Shah P, Cuthbert J, et al. Prevalence, pattern and clinical relevance of ultrasound indices of congestion in outpatients with heart failure. *Eur J Heart Fail* 2019; 21:904–916.
140. Lichtenstein DA. BLUE-protocol and FALLS-protocol: two applications of lung ultrasound in the critically ill. *Chest* 2015; 147:1659–1670.
141. Lichtenstein D. FALLS-protocol: lung ultrasound in hemodynamic assessment of shock. *Heart Lung Vessels* 2013; 5:142–147.
142. Lichtenstein DA. How can the use of lung ultrasound in cardiac arrest make ultrasound a holistic discipline. The example of the SESAME-protocol. *Med Ultrason* 2014; 16:252–255.
143. Mongodi S, De Luca D, Colombo A, et al. Quantitative lung ultrasound: technical aspects and clinical applications. *Anesthesiology* 2021; 134:949–965.

144. Torino C, Gargani L, Sicari R, et al. The agreement between auscultation and lung ultrasound in hemodialysis patients: the LUST study. *Clin J Am Soc Nephrol* 2016; 11:2005–2011.
145. Frassi F, Gargani L, Tesorio P, Raciti M, Mottola G, Picano E. Prognostic value of extravascular lung water assessed with ultrasound lung comets by chest sonography in patients with dyspnea and/or chest pain. *J Card Fail* 2007; 13:830–835.
146. Russell FM, Ehrman RR, Ferre R, et al. Design and rationale of the B-lines lung ultrasound guided emergency department management of acute heart failure (BLUSHED-AHF) pilot trial. *Heart Lung* 2019; 48:186–192.
147. Pang PS, Russell FM, Ehrman R, et al. Lung ultrasound-guided emergency department management of acute heart failure (BLUSHED-AHF): a randomized controlled pilot trial. *JACC Heart Fail* 2021; 9:638–648.
148. Gardelli G, Feletti F, Nanni A, Mughetti M, Piraccini A, Zompatori M. Chest ultrasonography in the ICU. *Respir Care* 2012; 57:773–781.
149. Llamas-Álvarez AM, Tenza-Lozano EM, Latour-Pérez J. Diaphragm and lung ultrasound to predict weaning outcome: systematic review and meta-analysis. *Chest* 2017; 152:1140–1150.
150. Buda N, Cylwik J, Mróz K. Lung ultrasound examination in patients with SARS-CoV-2 infection: multicenter study. *J Clin Med* 2021; 10:3255.
151. Senter R, Capone F, Pasqualin S, et al. Lung ultrasound patterns and clinical-laboratory correlates during COVID-19 pneumonia: a retrospective study from north East Italy. *J Clin Med* 2021; 10:1288.
152. Vassalou EE, Karantanas AH, Antoniou KM. Proposed lung ultrasound protocol during the COVID-19 outbreak. *J Ultrasound Med* 2021; 40:397–399.
153. Volpicelli G, Gargani L, Perlini S, et al. Lung ultrasound for the early diagnosis of COVID-19 pneumonia: an international multicenter study. *Intensive Care Med* 2021; 47:444–454.
154. Smargiassi A, Inchingolo R, Soldati G, et al. The role of chest ultrasonography in the management of respiratory diseases: document II. *Multidiscip Respir Med* 2013; 8:55.
155. Reissig A, Copetti R, Mathis G, et al. Lung ultrasound in the diagnosis and follow-up of community-acquired pneumonia: a prospective, multicenter, diagnostic accuracy study. *Chest* 2012; 142:965–972.
156. Görg C. Transcutaneous contrast-enhanced sonography of pleural-based pulmonary lesions. *Eur J Radiol* 2007; 64:213–221.
157. Quarato CMI, Cipriani C, Dimitri L, et al. Assessing value of contrast-enhanced ultrasound vs. conventional transthoracic ultrasound in improving diagnostic yield of percutaneous needle biopsy of peripheral lung lesions. *Eur Rev Med Pharmacol Sci* 2021; 25:5781–5789.
158. Sperandeo M, Rea G, Grimaldi MA, Trovato F, Dimitri LM, Carnevale V. Contrast-enhanced ultrasound does not discriminate between community acquired pneumonia and lung cancer. *Thorax* 2017; 72:178–180.
159. Findeisen H, Trenker C, Figiel J, Greene BH, Görg K, Görg C. Vascularization of primary, peripheral lung carcinoma in CEUS - a retrospective study (n = 89 patients). *Ultraschall Med* 2019; 40:603–608.
160. Sperandeo M, Sperandeo G, Varriale A, et al. Contrast-enhanced ultrasound (CEUS) for the study of peripheral lung lesions: a preliminary study. *Ultrasound Med Biol* 2006; 32:1467–1472.
161. Hong-Xia Z, Wen H, Ling-Gang C, et al. A new method for discriminating between bronchial and pulmonary arterial phases using contrast-enhanced ultrasound. *Ultrasound Med Biol* 2016; 42:1441–1449.
162. Safai Zadeh E, Dietrich CF, Kmoth L, et al. Peripheral pulmonary lesions in confirmed pulmonary arterial embolism: follow-up study of B-mode ultrasound and of perfusion patterns using contrast-enhanced ultrasound (CEUS). *J Ultrasound Med* 2022; 41:1713–1721. <https://doi.org/10.1002/jum.15852>.
163. Bartelt S, Trenker C, Görg C, Neesse A. Contrast-enhanced ultrasound of embolic consolidations in patients with pulmonary embolism: a pilot study. *J Clin Ultrasound* 2016; 44:129–135.
164. Trenker C, Apitzsch JC, Pastor S, Bartelt S, Neesse A, Goerg C. Detection of peripheral embolic consolidations using contrast-enhanced ultrasonography in patients with no evidence of pulmonary embolism on computed tomography: a pilot study. *J Clin Ultrasound* 2017; 45:575–579.
165. Jung EM, Stroszczyński C, Jung F. Contrast enhanced ultrasound (CEUS) to assess pleural pulmonary changes in severe COVID-19 infection: first results. *Clin Hemorheol Microcirc* 2020; 75:19–26.
166. Ciceri F, Beretta L, Scandroglio AM, et al. Microvascular COVID-19 lung vessels obstructive thromboinflammatory syndrome (MicroCLOTS): an atypical acute respiratory distress syndrome working hypothesis. *Crit Care Resusc* 2020; 22:95–97.
167. Bhagra A, Tierney DM, Sekiguchi H, Soni NJ. Point-of-care ultrasonography for primary care physicians and general internists. *Mayo Clin Proc* 2016; 91:1811–1827.
168. Conlon TW, Nishisaki A, Singh Y, et al. Moving beyond the stethoscope: diagnostic point-of-care ultrasound in pediatric practice. *Pediatrics* 2019; 144:e20191402.
169. Gentilotti E, De Nardo P, Cremonini E. Diagnostic accuracy of point-of-care tests in acute community-acquired lower respiratory tract infections. A systematic review and meta-analysis. *Clin Microbiol Infect* 2021.
170. Homar V, Gale ZK, Lainscak M, Svab I. Knowledge and skills required to perform point-of-care ultrasonography in family practice - a modified Delphi study among family physicians in Slovenia. *BMC Fam Pract* 2020; 21:56.
171. Myklestul HC, Skonnord T, Brekke M. Point-of-care ultrasound (POCUS) in Norwegian general practice. *Scand J Prim Health Care* 2020; 38:219–225.

172. Steinmetz P, Oleskevich S. The benefits of doing ultrasound exams in your office. *J Fam Pract* 2016; 65:517–523.
173. Flick D. Bedside ultrasound education in family medicine. *J Ultrasound Med* 2016; 35:1369–1371.
174. Hahn RG, Davies TC, Rodney WM. Diagnostic ultrasound in general practice. *Fam Pract* 1988; 5:129–135.
175. Wordsworth S, Scott A. Ultrasound scanning by general practitioners: is it worthwhile? *J Public Health Med* 2002; 24:88–94.
176. Shen-Wagner J, Deutchman M. Point-of-care ultrasound: a practical guide for primary care. *Fam Pract Manag* 2020; 27:33–40.
177. Wangüemert Pérez AL. Clinical applications of pulmonary ultrasound. *Med Clin (Barc)* 2020; 154:260–268.
178. Conangla L, Domingo M, Lupón J, et al. Lung ultrasound for heart failure diagnosis in primary care. *J Card Fail* 2020; 26: 824–831.
179. Boero E, Schreiber A, Rovida S, Vetrugno L, Blaivas M. The role of lung ultrasonography in COVID-19 disease management. *J Am Coll Emerg Physicians Open* 2020; 21:1357–1363.
180. Bonnel AR, Baston CM, Wallace P, Panebianco N, Kinoshian B. Using point-of-care ultrasound on home visits: the home-oriented ultrasound examination (HOUSE). *J Am Geriatr Soc* 2019; 67: 2662–2663.
181. Gregori G, Sacchetti R. Lung ultrasound in outpatient approach to children with suspected COVID 19. *Ital J Pediatr* 2020; 46:171.
182. Domingo M, Conangla L, Lupón J, et al. Lung ultrasound and biomarkers in primary care: partners for a better management of patients with heart failure? *J Circ Biomark* 2020; 9:8–12.
183. Aakjær AC, Brodersen J, Davidsen AS, Graumann O, Jensen MBB. Use and impact of point-of-care ultrasonography in general practice: a prospective observational study. *BMJ Open* 2020; 10:e037664.
184. Bornemann P, Jayasekera N, Bergman K, Ramos M, Gerhart J. Point-of-care ultrasound: coming soon to primary care? *J Fam Pract* 2018; 67:70–80.
185. Gordon CE, Feller-Kopman D, Balk EM, et al. Pneumothorax following thoracentesis: a systematic review and meta-analysis. *Arch Intern Med* 2010; 170:332–339.
186. Tanael M. Use of point-of-care ultrasonography in primary care to redress health inequities. *J Am Board Fam Med* 2021; 34: 853–855.
187. Epstein D, Petersiel N, Klein E, et al. Pocket-size point-of-care ultrasound in rural Uganda - a unique opportunity “to see,” where no imaging facilities are available. *Travel Med Infect Dis* 2018; 23:87–93.
188. Wong CL, Holroyd-Leduc J, Straus SE. Does this patient have a pleural effusion? *JAMA* 2009; 301:309–317.
189. Liu RB, Donroe JH, McNamara RL, Forman HP, Moore CL. The practice and implications of finding fluid during point-of-care ultrasonography: a review. *JAMA Intern Med* 2017; 177:1818–1825.
190. Lichtenstein D, Mezière G. A lung ultrasound sign allowing bedside distinction between pulmonary edema and COPD: the comet-tail artifact. *Intensive Care Med* 1998; 24:1331–1334.
191. Gargani L, Volpicelli G. How I do it: lung ultrasound. *Cardiovasc Ultrasound* 2014; 12:25.
192. Laursen CB, Hänselmann A, Posth S, Mikkelsen S, Videbæk L, Berg H. Prehospital lung ultrasound for the diagnosis of cardiogenic pulmonary oedema: a pilot study. *Scand J Trauma Resusc Emerg Med* 2016; 24:96.
193. Bianco F, Bucciarelli V, Ricci F, De Caterina R, Gallina S. Lung ultrasonography: a practical guide for cardiologists. *J Cardiovasc Med (Hagerstown)* 2017; 18:501–509.
194. Volpicelli G. Point-of-care lung ultrasound. *Praxis (Bern)* 1994) 2014; 103:711–716. <https://doi.org/10.1024/1661-8157/a001690>.
195. Sferrazza PGF, Mondoni M, Volpicelli G, et al. Point-of-care lung sonography: an audit of 1150 examinations. *J Ultrasound Med* 2017; 36:1687–1692.
196. Miglioranza MH, Gargani L, Sant’Anna RT, et al. Lung ultrasound for the evaluation of pulmonary congestion in outpatients: a comparison with clinical assessment, natriuretic peptides, and echocardiography. *JACC Cardiovasc Imaging* 2013; 6:1141–1151.
197. Gustafsson M, Alehagen U, Johansson P. Imaging congestion with a pocket ultrasound device: prognostic implications in patients with chronic heart failure. *J Card Fail* 2015; 21:548–554.
198. Platz E, Lewis EF, Uno H, et al. Detection and prognostic value of pulmonary congestion by lung ultrasound in ambulatory heart failure patients. *Eur Heart J* 2016; 37:1244–1251.
199. Miglioranza MH, Picano E, Badano LP, et al. Pulmonary congestion evaluated by lung ultrasound predicts decompensation in heart failure outpatients. *Int J Cardiol* 2017; 240:271–278.
200. Agricola E, Marini C. Lung ultrasound predicts decompensation in heart failure outpatients: another piece to the puzzle but still an incomplete picture. *Int J Cardiol* 2017; 240:324–325.
201. Radzina M, Biederer J. Ultrasonography of the lung. *Rofo* 2019; 191:909–923.
202. Diaz-Guzman E, Budev MM. Accuracy of the physical examination in evaluating pleural effusion. *Cleve Clin J Med* 2008; 75:297–303.
203. Nazerian P, Volpicelli G, Vanni S, et al. Accuracy of lung ultrasound for the diagnosis of consolidations when compared to chest computed tomography. *Am J Emerg Med* 2015; 33:620–625.
204. Martindale JL, Wakai A, Collins SP, et al. Diagnosing acute heart failure in the emergency department: a systematic review and meta-analysis. *Acad Emerg Med* 2016; 23:223–242.
205. Islam N, Ebrahimzadeh S, Salameh JP, et al. Thoracic imaging tests for the diagnosis of COVID-19. *Cochrane Database Syst Rev* 2021; 3:CD013639.
206. Kalokairinou-Motogna M, Maratou K, Paianid I, et al. Application of color Doppler ultrasound in the study of small pleural effusion. *Med Ultrason* 2010; 12:12–16.

207. Yousefifard M, Baikpour M, Ghelichkhani P, et al. Screening performance characteristic of ultrasonography and radiography in detection of pleural effusion; a meta-analysis. *Emerg (Tehran, Iran)* 2016; 4:1–10.
208. Volpicelli G, Mussa A, Garofalo G, et al. Bedside lung ultrasound in the assessment of alveolar-interstitial syndrome. *Am J Emerg Med* 2006; 24:689–696.
209. Picano E, Frassi F, Agricola E, et al. Ultrasound lung comets: a clinically useful sign of extravascular lung water. *J Am Soc Echocardiogr* 2006; 19:356–363.
210. Muniz RT, Mesquita ET, Souza Junior CV, Martins WA. Pulmonary ultrasound in patients with heart failure - systematic review. *Arq Bras Cardiol* 2018; 110:577–584.
211. Rivas-Lasarte M, Álvarez-García J, Fernández-Martínez J, et al. Lung ultrasound-guided treatment in ambulatory patients with heart failure: a randomized controlled clinical trial (LUS-HF study). *Eur J Heart Fail* 2019; 21:1605–1613.
212. Wang Y, Shi D, Liu F, Xu P, Ma M. Prognostic value of lung ultrasound for clinical outcomes in heart failure patients: a systematic review and meta-analysis. *Arq Bras Cardiol* 2021; 116:383–392.
213. Mhanna M, Beran A, Nazir S, et al. Lung ultrasound-guided management to reduce hospitalization in chronic heart failure: a systematic review and meta-analysis. *Heart Fail Rev* 2021; 469. <https://doi.org/10.1007/s10741-021-10085-x>.
214. Begot E, Grumann A, Duvoid T, et al. Ultrasonographic identification and semiquantitative assessment of unoculated pleural effusions in critically ill patients by residents after a focused training. *Intensive Care Med* 2014; 40:1475–1480.
215. Filopei J, Siedenburg H, Rattner P, et al. Impact of pocket ultrasound use by internal medicine housestaff in the diagnosis of dyspnea. *J Hosp Med* 2014; 9:594–597.
216. Blaivas M, Kuhn W, Reynolds B, Brannam L. Change in differential diagnosis and patient management with the use of portable ultrasound in a remote setting. *Wilderness Environ Med* 2005; 16:38–41.
217. Wongwaisayawan S, Suwannanon R, Sawatmongkornkul S, Kaewlai R. Emergency thoracic US: the essentials. *Radiographics* 2016; 36:640–659.
218. Corcoran F, Bystrycki A, Masud S, Mazur SM, Wise D, Harris T. Ultrasound in pre-hospital trauma care. *Trauma* 2015; 18:101–110.
219. Lichter Y, Topilsky Y, Taieb P, et al. Lung ultrasound predicts clinical course and outcomes in COVID-19 patients. *Intensive Care Med* 2020; 46:1873–1883.
220. Feletti F, Mucci V, Aliverti A. Chest ultrasonography in modern day extreme settings: from military setting and natural disasters to space flights and extreme sports. *Can Respir J* 2018; 2018: 8739704.
221. Scharonow M, Weillbach C. Prehospital point-of-care emergency ultrasound: a cohort study. *Scand J Trauma Resusc Emerg Med* 2018; 26:49.
222. Chrysou K, Halat G, Hokscho B, Schmid RA, Kocher GJ. Lessons from a large trauma center: impact of blunt chest trauma in poly-trauma patients-still a relevant problem? *Scand J Trauma Resusc Emerg Med* 2017; 25:42.
223. Kirkpatrick AW, Sirois M, Laupland KB, et al. Hand-held thoracic sonography for detecting post-traumatic pneumothoraces: the extended focused assessment with sonography for trauma (EFAST). *J Trauma* 2004; 57:288–295.
224. Zanobetti M, Coppa A, Nazerian P, et al. Chest abdominal-focused assessment sonography for trauma during the primary survey in the emergency department: the CA-FAST protocol. *Eur J Trauma Emerg Surg* 2018; 44:805–810.
225. Díaz-Gómez JL, Mayo PH, Koenig SJ. Point of care ultrasonography. *N Engl J Med* 2021; 385:1593–1602.
226. Rippey JC, Royse AG. Ultrasound in trauma. *Best Pract Res Clin Anaesthesiol* 2009; 23:343–362.
227. Lichtenstein D, Mezière G, Biderman P, Gepner A, Barré O. The comet-tail artifact: an ultrasound sign of alveolar interstitial syndrome. *Am J Respir Crit Care Med* 1997; 156:1640–1646.
228. Bouhemad B, Zhang M, Lu Q, Rouby JJ. Clinical review: bedside lung ultrasound in critical care practice. *Crit Care* 2007; 11:205.
229. Soldati G, Sher S. Bedside lung ultrasound in critical care practice. *Minerva Anesthesiol* 2009; 75:509–517.
230. Lobo V, Weingrow D, Perera P, Williams SR, Gharahbaghian L. Thoracic ultrasonography. *Crit Care Clin* 2014; 30:93–117.
231. Jambrik Z, Gargani L, Adamicz A, et al. B-lines quantify the lung water content: a lung ultrasound versus lung gravimetry study in acute lung injury. *Ultrasound Med Biol* 2010; 36:2004–2010.
232. Lichtenstein D, Meziere GA. Relevance of lung ultrasound in the diagnosis of acute respiratory failure: the BLUE protocol. *Chest* 2008; 134:117–125.
233. Mayo PH, Copetti R, Feller-Kopman D, et al. Thoracic ultrasonography: a narrative review. *Intensive Care Med* 2019; 45:1200.
234. Perrone T, Maggi A, Sgarlata C, et al. Lung ultrasound in internal medicine: a bedside help to increase accuracy in the diagnosis of dyspnea. *Eur J Intern Med* 2017; 46:61–65.
235. Koegelenberg CF, Von Groote-Bidlingmaier F, Bolliger CT. Transthoracic ultrasonography for the respiratory physician. *Respiration* 2012; 84:337–350.
236. Ramos-Hernández C, Botana-Rial M, Mouronte-Roibas C, et al. The diagnostic contribution of systematic lung ultrasonography in patients admitted to a conventional pulmonology hospitalization unit. *J Ultrasound Med* 2021; 41:575–584.
237. Maggi L, Biava AM, Fiorelli S, Coluzzi F, Ricci A, Rocco M. Lung ultrasound: a diagnostic leading tool for SARS-CoV-2 pneumonia: a narrative review. *Diagnostics (Basel)* 2021; 11:2381.
238. Yuriditsky E, Horowitz JM, Panebianco NL, Sauthoff H, Saric M. Lung ultrasound imaging: a primer for Echocardiographers. *J Am Soc Echocardiogr* 2021; 34:1231–1241.

239. Mento F, Perrone T, Macioce VN, et al. On the impact of different lung ultrasound imaging protocols in the evaluation of patients affected by coronavirus disease 2019: how many acquisitions are needed? *J Ultrasound Med* 2021 Oct; 40: 2235–2238.
240. Mathis G, Blank W, Reissig A, et al. Thoracic ultrasound for diagnosing pulmonary embolism: a prospective multicenter study of 352 patients. *Chest* 2005; 128:1531–1538.
241. Smargiassi A, Inchingolo R, Zanforlin A, Valente S, Soldati G, Corbo GM. Description of free-flowing pleural effusions in medical reports after echographic assessment. *Respiration* 2013; 85:439–441.
242. Smargiassi A, Inchingolo R, Calandriello C, et al. Possible role of chest ultrasonography for the evaluation of peripheral fibrotic pulmonary changes in patients affected by idiopathic pulmonary fibrosis-pilot case series. *Appl Sci* 2020; 10:1617.
243. Zanforlin A, Livi V, Santoriello C, et al. Ultrasound fissure observation: assessment of lung by pleural-hub affiliates. *Chest* 2018; 154:357–362.
244. Lovrenski J, Petrović S, Balj-Barbir S, Jokić R, Vilotijević-Dautović G. Stethoscope vs. ultrasound probe - which is more reliable in children with suspected pneumonia? *Acta Med Acad* 2016; 45:39–50.
245. Smargiassi A, Pasciuto G, Pedicelli I, et al. Chest ultrasonography in health surveillance of asbestos-related lung diseases. *Toxicol Ind Health* 2017; 33:537–546.
246. Smargiassi A, Inchingolo R, Chiappetta M, et al. Agreement between chest ultrasonography and chest X-ray in patients who have undergone thoracic surgery: preliminary results. *Multidiscip Respir Med* 2019; 14:9.
247. Kameda T, Kamiyama N, Taniguchi N. The mechanisms underlying vertical artifacts in lung ultrasound and their proper utilization for the evaluation of cardiogenic pulmonary edema. *Diagnostics* 2022; 12:252.
248. Feletti F, Malta B, Aliverti A. Assessment of diaphragm function by ultrasounds. In: Feletti F, Malta B, Aliverti A (eds). *Thoracic Ultrasound and Integrated Imaging*. Springer; 2017:109-299.
249. Summerhill EM, El-Sameed YA, Glidden TJ, McCool FD. Monitoring recovery from diaphragm paralysis with ultrasound. *Chest* 2008; 133:737–743.
250. Kim WY, Suh HJ, Hong SB, Koh Y, Lim CM. Diaphragm dysfunction assessed by ultrasonography: influence on weaning from mechanical ventilation. *Crit Care Med* 2011; 39:2627–2630.
251. Noda Y, Sekiguchi K, Kohara N, Kanda F, Toda T. Ultrasonographic diaphragm thickness correlates with compound muscle action potential amplitude and forced vital capacity. *Muscle Nerve* 2016; 53:522–527.
252. Nason LK, Walker CM, McNeeley MF, Burivong W, Fligner CL, Godwin JD. Imaging of the diaphragm: anatomy and function. *Radiographics* 2012; 32:E51–E70.
253. Sanchez de Toledo J, Munoz R, Landsittel D, et al. Diagnosis of abnormal diaphragm motion after cardiothoracic surgery: ultrasound performed by a cardiac intensivist vs. fluoroscopy. *Congenit Heart Dis* 2010; 5:565–572.
254. Lerolle N, Guérot E, Dimassi S, et al. Ultrasonographic diagnostic criterion for severe diaphragmatic dysfunction after cardiac surgery. *Chest* 2009; 135:401–407.
255. Matamis D, Soilemezi E, Tsagourias M, et al. Sonographic evaluation of the diaphragm in critically ill patients. Technique and clinical applications. *Intensive Care Med* 2013; 39:801–810.
256. Sarwal A, Walker FO, Cartwright MS. Neuromuscular ultrasound for evaluation of the diaphragm. *Muscle Nerve* 2013; 47:319–329.
257. Boussuges A, Gole Y, Blanc P. Diaphragmatic motion studied by m-mode ultrasonography: methods, reproducibility, and normal values. *Chest* 2009; 135:391–400.
258. Lichtenstein DA, Lascols N, Mézière G, Gepner A. Ultrasound diagnosis of alveolar consolidation in the critically ill. *Intens Care Med* 2004; 30:276–281.
259. Lichtenstein DA. Lung ultrasound in the critically ill. *Ann Intensive Care* 2014; 4:1.
260. Weinberg B, Diakoumakis EE, Kass EG, Seife B, Zvi ZB. The air bronchogram: sonographic demonstration. *AJR Am J Roentgenol* 1986; 147:593–595.
261. Lichtenstein D, Mézière G, Seitz J. The dynamic air bronchogram. An ultrasound sign of alveolar consolidation ruling out atelectasis. *Chest* 2009; 135:1421–1425.
262. Gillman LM, Panebianco N, Alkadi A, Blaivas M, Kirkpatrick AW. The dynamic sonographic air bronchogram: a simple and immediate bedside diagnosis of alveolar consolidation in severe respiratory failure. *J Trauma* 2011; 70:760.
263. Musolino AM, Tomà P, Supino MC, et al. Lung ultrasound features of children with complicated and noncomplicated community acquired pneumonia: a prospective study. *Pediatr Pulmonol* 2019; 54:1479–1486.
264. Inchingolo R, Copetti R, Smargiassi A, et al. Air bronchogram integrated lung ultrasound score to monitor community-acquired pneumonia in a pilot pediatric population. *J Ultrasound* 2021; 24: 191–200.
265. Hafez MR, Sobh ES, Elsayy SB, Abo-Elkheir OI. The usefulness of thoracic ultrasonography in diagnosis and staging of bronchogenic carcinoma. *Ultrasound* 2017; 25:200–212.
266. Soldati G, Smargiassi A, Inchingolo R, Sher S, Valente S, Corbo GM. Ultrasound-guided pleural puncture in supine or recumbent lateral position - feasibility study. *Multidiscip Respir Med* 2013; 8:18.
267. Solomon SD, Saldana F. Point-of-care ultrasound in medical education--stop listening and look. *N Engl J Med* 2014; 370: 1083–1085.
268. Kimura BJ. Point-of-care cardiac ultrasound techniques in the physical examination: better at the bedside. *Heart* 2017; 103:987.
269. Thapa A. Need of integrating Sonoscopy in undergraduate medical education in developing countries. *J Nepal Health Res Counc* 2020; 18.

270. Gillman LM, Kirkpatrick AW. Portable bedside ultrasound: the visual stethoscope of the 21st century. *Scand J Trauma Resusc Emerg Med* 2012; 20:18.
271. Breikreutz R, Dutiné M, Scheiermann P, et al. Thorax, trachea, and lung ultrasonography in emergency and critical care medicine: assessment of an objective structured training concept. *Emerg Med Int* 2013; 2013:312758.
272. Brant JA, Orsborn J, Good R, Greenwald E, Mickley M, Toney AG. Evaluating a longitudinal point-of-care-ultrasound (POCUS) curriculum for pediatric residents. *BMC Med Educ* 2021; 21:64.
273. Ma IWY, Arishenkoff S, Wiseman J, et al. Internal medicine point-of-care ultrasound curriculum: consensus recommendations from the Canadian internal medicine ultrasound (CIMUS) group. *J Gen Intern Med* 2017; 32:1052–1057.
274. Cuca C, Scheiermann P, Via G, et al. Assessment of a new e-learning system on thorax, trachea, and lung ultrasound. *Emerg Med Int* 2013; 2013:145361.
275. Nix K, Liu EL, Oh L, et al. A distance-learning approach to point-of-care ultrasound training (ADAPT): a multi-institutional educational response during the COVID-19 pandemic. *Acad Med* 2021; 96.
276. Soni NJ, Boyd JS, Mints G, et al. Comparison of in-person versus tele-ultrasound point-of-care ultrasound training during the COVID-19 pandemic. *Ultrasound J* 2021; 13:39.
277. Eke OF, Henwood PC, Wanjiku GW, Fasina A, Kharasch SJ, Shokoohi H. Global point-of-care ultrasound education and training in the age of COVID-19. *Int J Emerg Med* 2021; 14:12.
278. Lipsitz M, Levin L, Sharma V, et al. The state of point-of-care teleultrasound use for educational purposes. *J Ultrasound Med* 2022; 41:1889–1906.
279. European Federation of Societies for Ultrasound in Medicine and Biology (EFSUMB). “Building a European Ultrasound Community” Minimum Training Requirements for the Practice of Medical Ultrasound in Europe. Appendix 11: Thoracic Ultrasound [Internet]; 2009. www.efsumb.org/guidelines/2009-04-14apx11.pdf
280. Russell FM, Ferre R, Ehrman RR, et al. What are the minimum requirements to establish proficiency in lung ultrasound training for quantifying B-lines? *ESC Heart Fail* 2020; 7:2941–2947.
281. House DR, Amatya Y, Nti B, Russell FM. Lung ultrasound training and evaluation for proficiency among physicians in a low-resource setting. *Ultrasound J* 2021; 13:34.
282. Hayward SA, Janssen J. Use of thoracic ultrasound by physiotherapists: a scoping review of the literature. *Physiotherapy* 2018; 104: 367–375.
283. O'Dochartaigh D, Douma M, MacKenzie M. Five-year retrospective review of physician and non-physician performed ultrasound in a Canadian critical care helicopter emergency medical service. *Prehosp Emerg Care* 2017; 21:24–31.
284. Pietersen PI, Mikkelsen S, Lassen AT, et al. Quality of focused thoracic ultrasound performed by emergency medical technicians and paramedics in a prehospital setting: a feasibility study. *Scand J Trauma Resusc Emerg Med* 2021; 29:40.
285. Ball CG, Ranson MK, Rodriguez-Galvez M, Lall R, Kirkpatrick AW. Sonographic depiction of posttraumatic alveolar-interstitial disease: the hand-held diagnosis of a pulmonary contusion. *J Trauma* 2009; 66:962.
286. Kirkpatrick AW, McKee JL, Ball CG, Ma IWY, Melniker L. Empowering the willing: the feasibility of tele-mentored self-performed pleural ultrasound assessment for the surveillance of lung health. *Ultrasound J* 2022; 14:2.
287. Bouhemad B, Brisson H, Le-Guen M, Arbelot C, Lu Q, Rouby JJ. Bedside ultrasound assessment of positive end-expiratory pressure-induced lung recruitment. *Am J Respir Crit Care Med* 2011; 183:341–347.
288. Kirkpatrick AW, Ball CG, Rodriguez-Galvez M, Chun R. Sonographic depiction of the needle decompression of a tension hemo/pneumothorax. *J Trauma* 2009; 66:961.
289. Hoppmann RA, Rao VV, Bell F, et al. The evolution of an integrated ultrasound curriculum (iUSC) for medical students: 9-year experience. *Crit Ultrasound J* 2015; 7:18.
290. Celebi N, Griewatz J, Malek NP, et al. Development and implementation of a comprehensive ultrasound curriculum for undergraduate medical students - a feasibility study. *BMC Med Educ* 2019; 19:170.
291. Rao S, van Holsbeeck L, Musial JL, et al. A pilot study of comprehensive ultrasound education at the Wayne State University School of Medicine: a pioneer year review. *J Ultrasound Med* 2008; 27:745–749.
292. Jamniczky HA, McLaughlin K, Kaminska ME, et al. Cognitive load imposed by knobology may adversely affect learners' perception of utility in using ultrasonography to learn physical examination skills, but not anatomy. *Anat Sci Educ* 2015; 8: 197–204.
293. Lim JS, Lee S, Do HH, Oh KH. Can limited education of lung ultrasound be conducted to medical students properly? A pilot study. *Biomed Res Int* 2017; 2017:8147075.
294. Park S, Lee S, Do HH, Kim JS, Seo JS. Effectiveness of limited airway ultrasound education for medical students: a pilot study. *Clin Exp Emerg Med* 2019; 6:257–263.
295. Beaulieu Y, Laprise R, Drolet P, et al. Bedside ultrasound training using web-based e-learning and simulation early in the curriculum of residents. *Crit Ultrasound J* 2015; 7:1.
296. See KC, Ong V, Wong SH, et al. Lung ultrasound training: curriculum implementation and learning trajectory among respiratory therapists. *Intensive Care Med* 2016; 42:63–71.

297. McBeth P, Crawford I, Tiruta C, et al. Help is in your pocket: the potential accuracy of smartphone- and laptop-based remotely guided resuscitative teleultrasonography. *Telemed J E Health* 2013; 19: 924–930.
298. McBeth PB, Crawford I, Blaivas M, et al. Simple, almost anywhere, with almost anyone: remote low-cost telementored resuscitative lung ultrasound. *J Trauma* 2011; 71:1528–1535.
299. Biegler N, McBeth PB, Tiruta C, et al. The feasibility of nurse practitioner-performed, telementored lung teleultrasonography with remote physician guidance – “a remote virtual mentor”. *Crit Ultrasound J* 2013; 5:5.
300. Kirkpatrick AW. Clinician-performed focused sonography for the resuscitation of trauma. *Crit Care Med* 2007; 35:S162–S172.
301. Kirkpatrick AW, Hamilton DR, Nicolaou S, et al. Focused assessment with sonography for trauma in weightlessness: a feasibility study. *J Am Coll Surg* 2003; 196:833–844.
302. Pian L, Gillman LM, McBeth PB, et al. Potential use of remote teleultrasonography as a transformational technology in underresourced and/or remote settings. *Emerg Med Int* 2013; 2013:986160.
303. Kirkpatrick AW, McKee I, McKee JL, et al. Remote just-in-time telementored trauma ultrasound: a double-factorial randomized controlled trial examining fluid detection and remote knobology control through an ultrasound graphic user interface display. *Am J Surg* 2016; 211:894–902 e1.
304. Chiao L, Sharipov S, Sargsyan AE, et al. Ocular examination for trauma; clinical ultrasound aboard the international space station. *J Trauma* 2005; 58:885–889.
305. Fincke EM, Padalka G, Lee D, et al. Evaluation of shoulder integrity in space: first report of musculoskeletal US on the international space station. *Radiology* 2005; 234:319–322.
306. Sargsyan AE, Hamilton DR, Jones JA, et al. FAST at MACH 20: clinical ultrasound aboard the international space station. *J Trauma* 2005; 58:35–39.
307. Dyer D, Cusden J, Turner C, et al. The clinical and technical evaluation of a remote telementored teleultrasonography system during the acute resuscitation and transfer of the injured patient. *J Trauma* 2008; 65:1209–1216.
308. Crawford I, Tiruta C, Kirkpatrick AW, Mitchelson M, Ferguson J. Big brother could actually help quite easily: telementored “just-in-time” teleultrasonography of the FAST over a smartphone. *Ann Emerg Med* 2011; 58:312–314.
309. Crawford I, McBeth PB, Mitchelson M, Ferguson J, Tiruta C, Kirkpatrick AW. How to set up a low-cost tele-ultrasound capable video-conferencing system with wide applicability. *Crit Ultrasound J* 2012; 4.
310. Biegler N, McBeth PB, Tevez-Molina M, et al. Just-in-time cost-effective off-the-shelf remote telementoring of paramedical personnel in bed-side lung sonography – a technical case study. *Telemed J E Health* 2012 Dec; 18:807–809.
311. Crawford I, McBeth PB, Mitchelson M, Tiruta C, Ferguson J, Kirkpatrick AW. Telementorable “just-in-time” lung ultrasound on an iPhone. *J Emerg Trauma Shock* 2011; 4:526–527.
312. Di Gennaro F, Pizzol D, Marotta C, et al. Coronavirus diseases (COVID-19) current status and future perspectives: a narrative review. *Int J Environ Res Public Health* 2020; 17.
313. Ma IWY, Hussain A, Wagner M, et al. Canadian internal medicine ultrasound (CIMUS) expert consensus statement on the use of lung ultrasound for the assessment of medical inpatients with known or suspected coronavirus disease 2019. *J Ultrasound Med* 2021; 40:1879–1892.
314. Ng MY, Lee EYP, Yang J, et al. Imaging profile of the COVID-19 infection: radiologic findings and literature review. *Radiol Cardiothorac Imaging* 2020; 2:e200034.
315. Daszak P, das Neves C, Amuasi J, et al. Workshop Report on Biodiversity and Pandemics of the Intergovernmental Platform on Biodiversity and Ecosystem Services. Bonn, Germany; 2020. <https://doi.org/10.5281/zenodo.4147317>.
316. Nacoti N, Ciocca A, Giupponi G, et al. At the epicentre of the Covid-19 pandemic and humanitarian crises in Italy: Changing perspectives on preparation and mitigation. *NEJM Catal* 2020; 1.